

# paper 2

*by* Retno Supriyanti

---

**Submission date:** 21-Mar-2023 11:10PM (UTC+0700)

**Submission ID:** 2042755476

**File name:** Supriyanti\_2020\_IOP\_Conf.\_Ser.\_Mater.\_Sci.\_Eng.\_982\_012007.pdf (601.23K)

**Word count:** 3732

**Character count:** 19294

PAPER • OPEN ACCESS


## Simple Classification of the Alzheimer's Severity in Supporting Strengthening the Diagnosis of Patients based on ROC Diagram

To cite this article: Retno Supriyanti *et al* 2020 *IOP Conf. Ser.: Mater. Sci. Eng.* **982** 012007

View the [article online](#) for updates and enhancements.

### You may also like

- [Alzheimer's disease: biological aspects, therapeutic perspectives and diagnostic tools](#)  
M Di Carlo, D Giacomazza and P L San Biagio
- [A novel approach to brain connectivity reveals early structural changes in Alzheimer's disease](#)  
Marianna La Rocca, Nicola Amoroso, Alfonso Monaco et al.
- [Design, fabrication, optimization and characterization of memantine-loaded biodegradable PLGA nanoscaffolds for treatment of Alzheimer's disease](#)  
Varsha Rani and Ruchi Chawla



The Electrochemical Society  
Advancing solid state & electrochemical science & technology


243rd Meeting with SOFC-XVIII

Boston, MA • May 28 – June 2, 2023

Early registration discounts end **April 24!**

**Accelerate scientific discovery!**

Learn More & Register



## Simple Classification of the Alzheimer's Severity in Supporting Strengthening the Diagnosis of Patients based on ROC Diagram

Retno Supriyanti<sup>1,3</sup>, Ays Rahmadhani Subhi<sup>1</sup>, Egi Julian Ashari<sup>1</sup>, Fathoni Ahmad<sup>1</sup>, Yogi Ramadhani<sup>1</sup>, Haris B. Widodo<sup>2</sup>

<sup>1</sup>Electrical Engineering Department, Jenderal Soedirman University

<sup>2</sup>Medical Department, Jenderal Soedirman University

<sup>3</sup>retno\_supriyanti@unsoed.ac.id

**Abstract.** Alzheimer's disease is the most common cause of dementia and accounts for 60-80 percent of all cases of dementia. Dementia is a brain disorder that results in the loss of one's intellectual and social abilities. Progressive disease is one characteristic of this disease that interferes with a person's mental functions, such as memory and behavior. Experts believe that Alzheimer's disease interferes with part of the cell factory so that it does not go well. These scientists are not sure how this problem started, but like a real factory, backups, and disruptions in one system cause problems in other areas. When damage spreads, cells lose the ability to do work and eventually die, causing changes in the brain that cannot be changed. At present, the Conventional diagnosis of the severity of Alzheimer's is still carrying. The main objective of our research is to develop a Computer-Aided Diagnosis tool in the classification of the severity of Alzheimer's. This paper will discuss optimizing the use of the Receiver Operating Characteristics (ROC) parameter in identifying the severity of Alzheimer's. The main objective of this research is the development of automated Alzheimer's diagnoses in developing countries and rural areas that have limited health facilities and human resources. So even though the method used is relatively simple, it is proven to have a high level of accuracy above 90%. These results indicate that the use of this method has very promising results to be applied in developing countries and rural areas.

### 1. Introduction

Alzheimer's disease is a disease that attacks brain function, resulting in memory loss and other cognitive functions. This disease develops progressively, which is getting worse over time. Intellectual and social abilities in people living with Alzheimer's will continue to decline due to brain cells in people with Alzheimer's deteriorating and eventually dying. One part of what doctors do in diagnosing Alzheimer's is by scanning the brain. This examination is done to detect abnormalities or changes in the brain. Also, to ascertain the cause of the symptoms that appear. The brain scan method can be done with a CT scan or MRI. Based on the MRI image, the doctor can analyze the severity of a patient's Alzheimer's. However, unfortunately, to get a certain level of analysis, the MRI image that is used as a reference must be a high-resolution image. In reality, for many areas in developing countries such as Indonesia, hospitals may not necessarily have MRI machines, even if they have an MRI machine, then it is usually only MRI with low resolution. Another problem is, in developing countries, the



Content from this work may be used under the terms of the [Creative Commons Attribution 3.0 licence](https://creativecommons.org/licenses/by/3.0/). Any further distribution of this work must maintain attribution to the author(s) and the title of the work, journal citation and DOI.

Published under licence by IOP Publishing Ltd

neurologist is usually very limited in number. Also, in the analysis of radiological images, it is possible for human error in the analysis. To overcome these problems, we need a technique that can optimize the image of low-resolution MRI results while simultaneously analyzing the characteristics of determining the severity of Alzheimer's automatically.

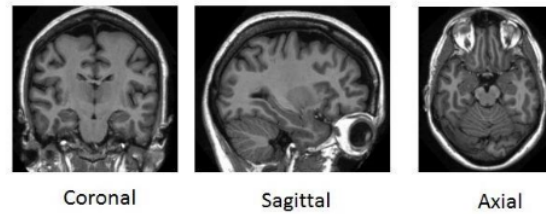
Alzheimer's disease is a disease that attacks brain function, resulting in memory loss and other cognitive functions. This disease develops progressively, which is getting worse over time. Intellectual and social abilities in people living with Alzheimer's will continue to decline due to brain cells in people with Alzheimer's deteriorating and eventually dying. One part of what doctors do in diagnosing Alzheimer's is by scanning the brain. This examination is done to detect abnormalities or changes in the brain. Also, to ascertain the cause of the symptoms that appear. The brain scan method can be done with a CT scan or MRI. Based on the MRI image, the doctor can analyze the severity of a patient's Alzheimer's. However, unfortunately, to get a certain level of analysis, the MRI image that is used as a reference must be a high-resolution image. In reality, for many areas in developing countries such as Indonesia, hospitals may not necessarily have MRI machines, even if they have an MRI machine, then it is usually only MRI with low resolution. Another problem is, in developing countries, the neurologist is usually very limited in number. Also, in the analysis of radiological images, it is possible for human error in the analysis. To overcome these problems, we need a technique that can optimize the image of low-resolution MRI results while simultaneously analyzing the characteristics of determining the severity of Alzheimer's automatically.

There is research on the diagnosis of Alzheimer's, which has been done by several people, including the following. Mikhno [1] developed the Voxels of Interest (VOI) template to control the subject treatment of people with AD. The developed VOI template can be used for both automatic and manual treatment. Boenink [2] analyzed diagnostic guidelines that could be used as a way to assess the existence of new technology in diagnosing Alzheimer's. Platero [3] introduced the analysis of longitudinal images, hippocampal segmentation, and classification of longitudinal boundaries in the diagnosis of Alzheimer's. Hajipour [4] conducted a review of nanotechnology for Alzheimer's diagnosis and therapy and discussed his accuracy so far. Heung-II [5] proposed a multi-task learning method for feature selection in the classification of computer-based Alzheimer's diagnosis. In his research, he uses a multi-peak class distribution. In this case, he uses the grouping method to get the characteristics of the multi-peak distribution and defines the subclasses based on the results of the grouping. Balamurugan [6] he proposed reducing the KNN Algorithm-based dimension to analyze and clarify the severity of Alzheimer's. Baiying [7] proposed an analysis of discriminatory features and an analysis of canonical correlations in Alzheimer's disease. This method is proposed to improve performance in exploring data from various modalities. Baig [8] discussed peptide compounds for initial diagnosis and treatment of Alzheimer's and their development in a variety of ways regarding applications in Alzheimer's disease. Liu [9] proposed the construction of multilevel convolutional neural networks to analyze the features of various modalities in MRI and PET brain images to classify the severity of Alzheimer's. Zhu [10] proposed a method for converting the original features of various modalities into a comparable general form for canonical correlation analysis in Alzheimer's classification. Our research focuses on the development of Computer Aided Diagnosis in helping to speed up the diagnosis of Alzheimer's based on MRI images that have a low resolution as is the case in many developing countries, although this system is also possible to be applied in developed countries. In our previous papers [11] [12] [13][14] [15] we discussed the segmentation of the hippocampus and ventricular regions which are important areas in diagnosing the severity of Alzheimer's. But in our previous paper, we have not yet discussed the Alzheimer's classification method based on the results of segmentation. Referring to this, then in this paper we discuss a simple method of classifying the severity of Alzheimer's by using a ROC curve based on Clinical Dementia Rating (CDR) values.

## 2. Research Methods

### 2.1. Input Images

All data used in this research came from the Open Access Series of Imaging Studies (OASIS) databases [16][17][18][19]. Images from OASIS have been grouped into CDR 0, CDR 1 and CDR 2. In previous research we also pre-processed the image so that the input image is ready to be analyzed, for example by doing image enhancement and segmentation of the hippocampus and ventricular areas using the active contour and watershed segmentation methods [11] [12] [13][14][15]. In this paper, we conducted an experiment by developing a very simple classification method, in classifying the severity of Alzheimer's based on CDR values. Figure 1 shows an example of the input image of the three types of axial, sagittal and coronal slices.



**Fig.1.** Examples of the input image

### 2.2. Receiver Operating Characteristics (ROC) for Determination of Pixel Characteristics in Segmentation

The ROC curve was first used by electrical engineers and radar technicians during the Second World War to detect enemy objects on the battlefield, then this is known as signal detection theory. ROC analysis has subsequently evolved and has been used in medicine, radiology, as well as in several other fields for decades. Further ROC analysis has been introduced in relatively new fields such as machine learning and data mining [20]. ROC is a measurement in diagnostic tests, in the medical world, these measurements are used for evaluating medical tests, for example, to compare a new device with standard medical equipment that is standard. A segmentation application must have sufficient accuracy, to meet these requirements, researchers use the ROC measurement method, which is to calculate the ratio of False Positive (FP) and False Negative Ratio (FN) on the segmented image by comparing the results of the experimental image segmentation on the original image. Suppose there is a classification problem with two classes. We can consider each pair of data  $I$  to map a set of elements  $\{p, n\}$  as positive class labels and negative class labels. The classification model maps the pair of data to the predicted class. To distinguish the actual class from the predicted class, the predicted class is symbolized by  $\{Y, N\}$ . In terms of identifying sick and healthy images, the mapping will produce four outputs, namely TP, TN, FP, and FN. In contrast to the evaluation parameters for pixel segmentation, TP in identification is image data that is diagnosed by doctors as a sick image, correctly detected pain after going through hypothesis testing, whereas FP is image data with a health diagnosis but is indicated incorrectly as a sick image after testing, TN is image data that is diagnosed by doctors as being healthy, correctly detected healthy. After going through hypothesis testing, and FN is image data with a diagnosis of pain but is indicated incorrectly as a healthy image after testing. The parameters used as performance indicators in this research are those shown by Equation 1 through equation 5.

$$\text{Sensitivity (Se)} = \frac{TP}{TP+FN} = \frac{TP}{nD} \quad (1)$$

$$\text{Specificity (Sp)} = \frac{TN}{FP+TN} = \frac{TN}{nC} \quad (2)$$

$$Accuracy = \frac{TP + TN}{TP + TN + FP + FN} \quad (3)$$

$$PPV = \frac{TP}{(TP + FP)} = \frac{TP}{nP} \quad (4)$$

$$NPV = \frac{TN}{(TN + FN)} = \frac{TN}{nN} \quad (5)$$

Positive Predictive Value (PPV) is the possibility that people with positive test results (images declared sick) will have the conditions tested. NPV is the possibility that people with negative test results (otherwise healthy images) do not have that condition. The ROC curve shows the tradeoff between the level at which a model can recognize positive data accurately and the level at which the model incorrectly recognizes negative data as positive data.

### 3. Result and Discussion

As explained in the above paragraph, that in our previous research, we have succeeded in segmenting the three sagittal, axial, and coronal slices in localizing the ventricular and hippocampal areas. In this paper, the emphasis is on identifying the severity of Alzheimer's. Because the ultimate goal of this research is the development of simple technology, it can be used as an accelerator for diagnosing the severity of Alzheimer's especially in developing countries and rural areas to pursue industrial technology 4.0 especially in health, so we use identification based on the ROC curve only. In the sagittal slice, three areas are classified as the left hippocampus, right hippocampus, and ventricle. Table 1, Table 2, and Table 3 show the average values of the right hippocampus, left hippocampus, and ventricle areas according to sagittal slice.

**Table 1.** The average value of the right hippocampus left hippocampus and ventricle area based on the sagittal slice.

	Right Hippocampus		Left Hippocampus		Ventricle	
	Alzheimer	Healthy	Alzheimer	Healthy	Alzheimer	Healthy
<b>TP</b>	108.5	100.7	85.8	50.1	1259.6	946.9
<b>TN</b>	2981.1	2900.2	2960.7	2848.7	7846.7	8112.8
<b>FP</b>	92.8	173.5	113.3	225.2	315.2	49.10
<b>FN</b>	103.5	108.8	126.1	154.1	154.3	469.7
<b>Se</b>	51.1	48.5	40.5	27.0	89.0	66.8
<b>Sp</b>	96.9	94.3	96.3	92.6	96.1	99.3
<b>Ac</b>	94.0	91.4	92.7	88.4	95.0	94.5
<b>RFP</b>	0.0302	0.0564	0.0368	0.0732	0.038	0.006
<b>RFN</b>	0.4882	0.5141	0.5949	0.7297	0.109	0.331

According to Table 1, the FP values in the Alzheimer's image have an average value less than the FP values in the healthy image. This shows that the object with Alzheimer's has a smaller number of pixels than the reference object. However, this is the opposite of the results obtained in the measurement of the ventricle area as shown in Table 3. Referring to our previous research [12][13][14][15], for the hippocampus area we use pixels for reference image is 212, while for the ventricle area is 1557. Using Equation 1 to 5, we obtained the accurate identification of the severity of

Alzheimer's by 96% for the right hippocampus, 98% for the left hippocampus, and 91% for ventricle areas based on sagittal slices.

In the axial slice, the only area that can be analyzed is the hippocampus area. Table 4 shows the average value of the results of the segmentation of the hippocampus area based on axial slices. Referring to Table 2, RFP values increase and RFN decreases along with the sequence based on the smallest pixel area until the largest pixel in the healthy test image data. RFP is the ratio between pixels that should not be vessels in the reference image but segmented as vessel pixels. In images with Alzheimer's, the RFN shows a greater value than the RFP, and the FN ratio graph increases as the number of pixels decrease from the test image. This shows that objects with Alzheimer's diagnosis have fewer pixel counts than reference objects so that the RFP is small. Conversely, objects with healthy diagnoses have more pixels than reference objects so that the RFP is high. Identification results through the ROC parameters stated in Equations 1 to 5 give an accuracy value of 98%.

**Table 2.** The average value of the hippocampus area based on an axial slice

	Hippocampus	
	Alzheimer	Healthy
<b>TP</b>	303.25	435.15
<b>TN</b>	1968.083	1851.5
<b>FP</b>	56.666	211.25
<b>FN</b>	272.25	30.5
<b>Se</b>	53.951	93.277
<b>Sp</b>	97.087	89.737
<b>Ac</b>	87.206	90.333
<b>RFP</b>	0.029	0.102
<b>RFN</b>	0.460	0.067

In the coronal slice, the area analyzed is the ventricle and the hippocampus but does not distinguish between the right and left hippocampus. Table 3 shows the average value of ventricle and hippocampus areas based on coronal slices.

**Table 3.** Average value of ventricle and hippocampus area based on coronal slice

	Ventricle		Hippocampus	
	Alzheimer	Healthy	Alzheimer	Healthy
<b>TP</b>	439.2	274.4	80.7	274.4
<b>TN</b>	30327.06	30458.8	614.9	30458.8
<b>FP</b>	175.9	44.1	30.0	44.3
<b>FN</b>	33.8	198.5	57.2	198.5
<b>Se</b>	92.03	58.02	54.01	89.47
<b>Sp</b>	99.54	99.85	95.07	84.49
<b>RFP</b>	0.005	0.001	0.04	0.15
<b>RFN</b>	0.001	0.006	0.07	0.01

According to Table 3, RFP and RFN values represent the pixel characteristics of the segmented results with the reference image. The ratio value of 0 to 1, if the image has a lot of segmentation areas following the reference image, the ratio will be of high value. From the test results, it can be concluded that Alzheimer's image for ventricular objects has a higher number of pixels than the healthy image with an average value of RFP 0.005 and RFN 0.001. According to Table 3, In images

with Alzheimer's, the RFN shows a greater value than the RFP. This shows that objects with Alzheimer's have fewer pixel counts than reference objects so that the RFN is large. Vice versa, the object with a health diagnosis has more pixels than the reference object so that the RFN is of low value. Based on the test results, it can be concluded that Alzheimer's image for hippocampus objects has a lower pixel count than in healthy images with RFP values of 0.04 and RFN of 0.07. Identification results through the ROC parameters provide an accuracy value of 86.3% for the ventricle area and 98.4% for the hippocampus area.

#### 4. Conclusion

The experimental results show that in almost all types of slices, implementation using ROC parameters shows a performance value of more than 90%. So if the system that we develop can be applied to health service units in developing countries and rural areas, it will support the implementation of the industrial revolution 4.0, especially in the field of health services

#### 5. Acknowledgment

It is supported by the Ministry of Education and Culture through "Fundamental Research" Scheme fiscal year 2020. We also thank the Open Access Series of Imaging Studies (OASIS) datasets for all MRI data used in this research.

#### 6. Reference

- [1] Mikhno A, Devanand D, Pelton G, Cuasay K, Gunn R, and Al E 2008 Voxel-Based Analysis of sup 11 C-PIB Scans for Diagnosing Alzheimer ' s Disease *J Nucl Med.* **49** (8).
- [2] Boenink M 2018 Gatekeeping and trailblazing: The role of biomarkers in novel guidelines for diagnosing Alzheimer's disease *Biosocieties* **13** (1), 213–231.
- [3] Platero C, Lin L, and Tobar M C 2019 Longitudinal Neuroimaging Hippocampal Markers for Diagnosing Alzheimer's Disease *Neuroinformatics.* **17**(1), 43–61.
- [4] Hajipour M J, Santoso M R, Rezaee F, Aghaverdi H, Mahmoudi M, and Perry G 2017 Advances in Alzheimer's Diagnosis and Therapy: The Implications of Nanotechnology *Trends Biotechnol.* **35** (10) 9.
- [5] Suk H I and Shen D 2014 Subclass-based multi-task learning for Alzheimer's disease diagnosis *Front. Aging Neurosci.* **6** no. JUN 1–20.
- [6] Balamurugan M, Nancy A, and Vijaykumar S 2017 Alzheimer's disease diagnosis by using dimensionality reduction based on KNN Classifier, *Biomed Pharmacol J* **10** (4) 1823–1830.
- [7] Lei B, Chen S, Ni D, and Wang T 2016 Discriminative learning for Alzheimer's disease diagnosis via canonical correlation analysis and multimodal fusion *Front. Aging Neurosci.* **8** no. MAY, 1–18.
- [8] Baig M H, Ahmad K, Rabbani G, and Choi I 2018 Use of peptides for the management of Alzheimer's disease: Diagnosis and inhibition *Front Aging Neurosci.* **10**, no. FEB, 1–7, 2018.
- [9] Liu M, Cheng D, Wang K, and Wang Y, 2018 Multi-Modality Cascaded Convolutional Neural Networks for Alzheimer's Disease Diagnosis *Neuroinformatics*, **16** (3–4).
- [10] Zhu X, Suk H I, Lee S W, and Shen D 2016 Canonical feature selection for joint regression and multi-class identification in Alzheimer's disease diagnosis *Brain Imaging Behav.* **10**, (3) 818–828.
- [11] Supriyanti R, Subhi A R, Ramadhani Y, and Widodo H B 2019 Coronal slices segmentation of mri images using active contour method on initial identification of alzheimer severity level based on clinical dementia rating (CDR) *J. Eng. Sci. Technol.* **14** (3) 1672–1686.
- [12] Supriyanti R, Fanthoni A, Ashari E J, Ramadhani Y, and Widodo H B 2019 Active Contour Method for Identifying Area of Sagittal and Axial Slices to Identify the Severity of Alzheimer's disease, *International Conference on Recent Advances in Engineering and*



*Technology (ICRAET).*

- [13] Supriyanti R, Subhi A R, Ramadhani Y, and Widodo H B, 2019 CORONAL SLICES SEGMENTATION OF MRI IMAGES USING ACTIVE CONTOUR METHOD ON INITIAL IDENTIFICATION OF ALZHEIMER SEVERITY LEVEL BASED ON CLINICAL DEMENTIA RATING (CDR) *J. Eng. Sci. Technol.* **14** (3)1672–1686.
- [14] Supriyanti R, Subhi A R, Ramadhani Y, and Widodo H B 2018 A Simple Tool For Identifying The Severity of Alzheimer's Based on Hippocampal and Ventricular Size Using A ROC Curve on a Coronal Slice Image *Asian J. Inf. Technol.* **17** (7) 321–327,.
- [15] Supriyanti R, Subhi A R, Ramadhani Y, and Widodo H B 2018 Calculating Ventricle's Area based on Clinical Dementia Rating (CDR) Values on Coronal MRI image *20th International Conference on Computer-Based Patient Records and Error Prevention (ICCPREP)* 2018.
- [16] Buckner R 2004 A unified approach for morphometric and functional data analysis in young, old, and demented adults using automated atlas-based head size normalization: reliability and validation against manual measurement of total intracranial volume. *Neuroimage.* **23** 724–738.
- [17] Rubin E 1998 A prospective study of cognitive function and onset of dementia in cognitively healthy elders *Arch Neurol.* **55** 395–401.
- [18] Zhang Y, Brady M, and Smith S 2001 Segmentation of brain MR images through a hidden Markov random field model and the expectation maximization algorithm *IEEE Trans. Med. Imaging* **20** (1) 45–57.
- [19] Fotenos A, Snyder A, Girton L, Morris J, and Buckner R 2005 Normative estimates of cross-sectional and longitudinal brain volume decline in aging and AD *Neurology.* **64** 1032–1039.
- [20] Fawcett T 2006 An introduction to ROC analysis *Pattern Recognit* **27** 861–874.

# paper 2

## ORIGINALITY REPORT

14%  
SIMILARITY INDEX

11%  
INTERNET SOURCES

9%  
PUBLICATIONS

4%  
STUDENT PAPERS

## MATCH ALL SOURCES (ONLY SELECTED SOURCE PRINTED)

2%  
★ Submitted to Bowling Green State University  
Student Paper

Exclude quotes      Off  
Exclude bibliography      On

Exclude matches      Off