

A comparison of the effectiveness banana stem sap and virgin coconut oil on diabetic wound healing

by Yunita Sari

Submission date: 03-Jan-2022 10:19AM (UTC+0700)

Submission ID: 1736987362

File name: Sari_2021_IOP_Conf._Ser._Earth_Environ._Sci._746_012018.pdf (6.93M)

Word count: 3482

Character count: 17534

PAPER • OPEN ACCESS

A comparison of the effectiveness banana stem sap and virgin coconut oil on diabetic wound healing

To cite this article: Yunita Sari *et al* 2021 *IOP Conf. Ser.: Earth Environ. Sci.* **746** 012018

View the [article online](#) for updates and enhancements.

You may also like

- [IMPLICATIONS FOR THE FORMATION OF BLUE STRAGGLER STARS FROM HST ULTRAVIOLET OBSERVATIONS OF NGC 188](#)
Natalie M. Gosnell, Robert D. Mathieu, Aaron M. Geller et al.
- [FORMATION AND EVOLUTION OF BLUE STRAGGLERS IN 47 TUCANAE](#)
Javiera Parada, Harvey Richer, Jeremy Heyl et al.
- [ON THE TRIPLE ORIGIN OF BLUE STRAGGLERS](#)
Hagai B. Perets and Daniel C. Fabrycky



The Electrochemical Society
Advancing solid state & electrochemical science & technology

241st ECS Meeting

May 29 – June 2, 2022 Vancouver • BC • Canada
Extended abstract submission deadline: Dec 17, 2021

Connect. Engage. Champion. Empower. Accelerate.
Move science forward



 **Submit your abstract**

A comparison of the effectiveness banana stem sap and virgin coconut oil on diabetic wound healing

Yunita Sari^{1,*}, Atyanti Isworo¹, Arif Setyo Upoyo¹, Annas Sumeru¹, Dhadhang Wahyu Kurniawan², Eman Sutrisna³

¹Department of Nursing, Faculty of health sciences, Universitas Jenderal Soedirman, Indonesia

²Department of Pharmaceutics, Universitas Jenderal Soedirman, Indonesia

³Department of Pharmacology, Faculty of medicine, Universitas Jenderal Soedirman, Indonesia

*Email : yunita.sari@unsoed.ac.id

Abstract. Banana stem sap (BSS) and virgin coconut oil (VCO) is usually used for wound care treatment. However, to date, no study has been conducted to compare the effectiveness of these two therapies. Therefore, this study aimed to compare the effectiveness of BSS and VCO on diabetic wound healing in rats. Male Wistar rats were randomly divided into 3 groups depending on the formulation used on the wound: BSS, VCO, and control-treated with film dressing. The tissue samples were obtained on days 4, and 14. The wound size, the presence of necrotic tissue, level of inflammation, level of fibroblast, and re-epithelialization were assessed. On day 10, wounds in the BSS group were the smallest compared with other groups. The necrotic tissue and level of inflammation in the BSS group were also less as compared with other groups. The re-epithelialization in BSS group was also the most advance compared with other groups. Our study showed that the ability of BSS in accelerating wound healing is better than VCO and film dressing. We recommend nurses and clinician in Indonesia to use BSS to treat diabetic ulcer.

1. Introduction

The number of patients with diabetes mellitus (DM) in the world, including Indonesia, has become alarming because of its dramatic increase. It has been predicted that Indonesia will reach sixth place with regard to the number of people with DM in the world in 2030. The increase of people with DM will also cause an increase of DM complications, especially diabetic ulcers. A previous study showed that approximately 26,1 million people with DM suffer from diabetic ulcers. Diabetic ulcers can become infected, leading to invasive systemic infection and mortality. Indeed, the 5-year mortality rate from the diabetic ulcer is 74%. The highest mortality rate due to diabetic ulcer occurs in low and middle-income countries [1].

In order to improve wound healing, advanced wound care technology is usually used for diabetic ulcer [2]. However, advanced technology is usually rare in Indonesia. Therefore, many herbals and natural products are often used as a wound healer. The herbals and natural products exert a promising effects in the wound management since many of them can facilitate disinfection, debridement, and provide a moist environment. Natural products, which are widely used in Indonesia rural areas to treat wounds, are banana stem sap (BSS) and virgin coconut oil (VCO)[3].



Content from this work may be used under the terms of the [Creative Commons Attribution 3.0 licence](https://creativecommons.org/licenses/by/3.0/). Any further distribution of this work must maintain attribution to the author(s) and the title of the work, journal citation and DOI.

Published under licence by IOP Publishing Ltd

Banana plants usually grow in south east Asia, including Indonesia [4]. They contain many beneficial factors such as catecholamine, iron, vitamin B and C, albuminoids, fats, and mineral salts [4–6]. Banana stem sap (BSS) is the part of banana plant that shows most of the beneficial effects. Indeed, BSS contains the mentioned factors plus also flavonoids, saponins, and tannins that work as antioxidants, and they exert antibacterial, antifungal, and pain relief effect [4]. In addition, BSS contains lectin that stimulates skin cell growth (angiogenesis) [7]. As regard the wound healing process, a study of Priosoeryanto et al (2007) in an acute wound model showed that BSS can reduce inflammation in an incision wound and improve the number of fibroblasts and the amount of granulation tissue [8].

VCO has been widely used to treat microbial infections and skin problems and in eastern Indonesia to treat wounds [9]. VCO contains many antioxidants such as polyphenols, tocopherol, ferulic acid, phenolic acid and flavonoids, and also vitamin E [10]. VCO also has antimicrobial properties [9]. As regard wound healing, VCO can reduce inflammation in palatoplasty surgical wound and VCO flavonoids can improve wound re-epithelialization, increase anti-oxidant level, and increase the amount of granulation tissue [11]. Moreover, VCO can reduce infection [9].

According to the aforementioned properties of BSS and VCO, both these topical therapies could be candidate for wound care treatment. However, it is also important to evaluate which of these two therapies is more effective in promoting wound healing, since no study is available that directly compared these two plant extracts. Therefore, the purpose of this study was to compare the effectiveness of BSS and VCO in the promotion of diabetic ulcer healing.

2. Materials and methods

2.1. Animals

Healthy Male Wistar Rats (180-200 grams) were obtained from the Laboratory of animal, Department of Pharmaceutical, Universitas Muhammadiyah Purwokerto, Indonesia. Rats were housed in one cage per rat and they have free access to food and drink *ad libitum*. Our study protocol was approved by the ethical committee of the Faculty of Medicine, Universitas Jenderal Soedirman, Indonesia.

2.2. Herbal extracts

The VCO used in this study was commercially available and purchased from the small industry CV Al Afiat, and was approved by the local authority of BPOM, the Indonesia FDA-like agency. This product was 100% VCO and was ready to use. The BSS used in this study was purchased from a local shop. The processing was performed at the Department of Pharmacy, Universitas Jenderal Soedirman, Purwokerto, Indonesia.

The preparation of the BSS was performed according to previous study with some modifications [12,13]. In brief, the outer green part of the banana stem was peeled off and the inner portion was cut into small pieces. The pieces were then crushed and approximately 100 ml juice was extracted. The obtained liquid was applied to the wound using a swab. Every day of wound treatment, the remaining of liquid was freshly made, the remaining of liquid was thrown away.

2.3. Induction of diabetic rats and experimental procedure

Rats were injected with alloxan monohydrate 90 mg/Kg of body weight to induce diabetes mellitus based on previous study [14]. The glucose level higher than 275 mg/dl was considered diabetes mellitus. The rat was anesthetised with ketamine hydrochloride (25-30 mg/kg body weight). The wounding procedure was conducted based on the previous study [15]. In brief, one wound of 1 cm in size was created on the rat back dorsal region. Diabetic rats were divided into 3 groups depending on the formulation used on the wound: (1) BSS, (2) VCO (3) and control treated with film dressing. In the BSS and VCO groups, 50 µL corresponding extract was applied. The wounds were cleansed every day. During wound cleaning, the wound condition were recorded.

2.4. Wound areas

ImageJ software was used to measure wound areas [16]. Relative wound area was calculated as follows: $\text{size at day } n - \text{size at day } 0 / (\text{size at day } 0)[14]$. Rats were sacrificed by overdose of anesthesia. The wound tissue along with surrounding normal skin was harvested on day 4, and 14 and fixed in 10% formalin for histological analysis.

2.5. Hematoxylin and eosin (HE) staining

The tissue immersed in formalin 10% underwent a series of dehydrations in alcohol and xylene and embedded in paraffin. Next, the tissue was cut into 4 μm thick slices using a microtome. Slices were deparaffinized, rehydrated in xylene and alcohol, and stained with HE. After mounting, sections were observed and analyzed under a microscope. The intensity of polymorphonuclear neutrophils (PMNs) and fibroblast was assessed based on previous study [51].

2.6. Statistical analysis

Statistical analysis was performed using SPSS 21 software package. Wound size was expressed as mean \pm standard deviation (SD). Differences in wound size, fibroblast intensity and inflammation intensity among groups were analyzed by ANOVA or Kruskal Wallis test. If a significant difference was found, post-hoc Tukey's HSD test or Mann-Whitney U-test was used. A value of $p < 0.05$ was considered statistically significant.

3. Results

3.1. Wound bed appearance

The wound bed appearance is shown in Figure 1. On day 1, the wound appearance was red in all groups, and no slough appeared. On day 3, the wound bed in both BSS and VCO group did not have slough, while a thin slough appear in the wounds of the control group, but the wound bed in the BSS group was redder compared with the one of the VCO group. On day 5, the wound bed in all groups was covered by a thin slough. On day 11, the slough was disappeared in the BSS group, while the wound bed in VCO and control group was still covered by slough. On day 14, the wounds in BSS group were almost healed and were covered with new epithelium, while in the VCO group, wounds were still covered with slough. The wound in the control group on day 14 showed no necrotic tissue and the wound bed was filled with granulation tissue.

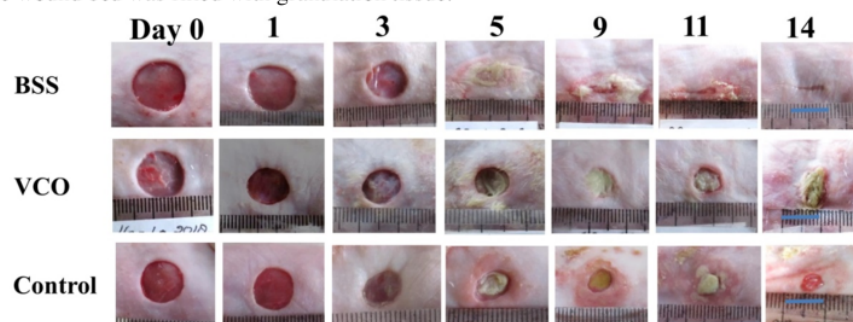


Figure 1. Wound bed appearance.

There is no difference in the wound size among the three groups on inflammation phase and early proliferative phase. However, from day 9 onwards, wounds in the BSS group were significantly smaller compared with the ones in the VCO group (day 9, $p=0.034$; day 10, $p=0.034$, day 11, $p=0.34$, day 12, $p=0.034$, day 13, $p=0.034$, and day 14, $p=0.034$) and control group (day 9, $p=0.043$; day 10,

$p=0.043$, day 11, $p=0.042$, day 12, $p=0.042$, day 13, $p=0.021$, day 14, $p=0.021$). On day 9, no significant difference was observed between control and VCO group regarding wound size. However, from day 10 onwards, wounds in the control group were significantly smaller compared with the ones in the VCO group (day 10, $p=0.034$; day 11, $p=0.032$, day 12, $p=0.032$, day 13, $p=0.034$, day 14, $p=0.034$).

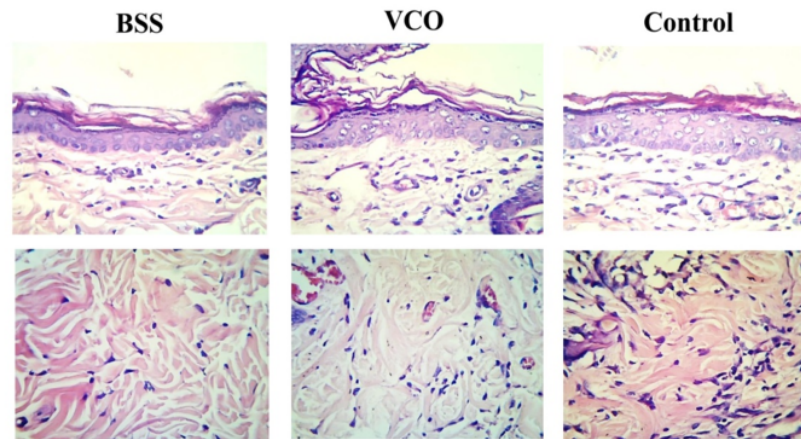


Figure 2. HE staining of epidermis (upper picture) and dermis (lower picture) in the BSS, VCO, and control group on day 4.

3.2. He staining

The result of HE staining in epidermis and dermis layer on day 4, and 14 are shown in figure 2, and 3, respectively. Figure 2 shows that the intensity of polymorphonuclear (PMNs) in BSS group was slightly lower than that in control group and VCO groups. The inflammation in the VCO group was also slightly lower than that in control group. Figure 2 also shows that no significant difference was found in the intensity of fibroblast among the three groups on day 4. The result of HE staining on day 14 showed that the intensity of PMNs in BSS group was not only significantly lower compared with control group ($p = 0.008$), but also compared with VCO group ($p = 0.008$). In addition, the level of PMNs in the VCO group was significantly higher than that in the control group ($p = 0.008$). On day 14, the intensity of fibroblast in BSS group was significantly higher compared with control ($p = 0.008$) and VCO group ($p = 0.04$) (Table 1). Figure 3 also shows that the re-epithelialization was most advanced in the BSS groups compared with the other groups.

Table 1. The difference in the intensity of PMNs and Fibroblast in each group on day 14.

Groups	PMNs	Fibroblast
BSS	1*†	3*†
VCO	3*	2
Control	2	2

Values represent the median score. Scores can range from 0 to 4 (0 = absent; 1 = occasional; 2 = moderate; 3 = abundant; 4 = very abundant). * $p < 0.05$ (BSS/VCO vs control), † $p < 0.05$ (BSS vs VCO)

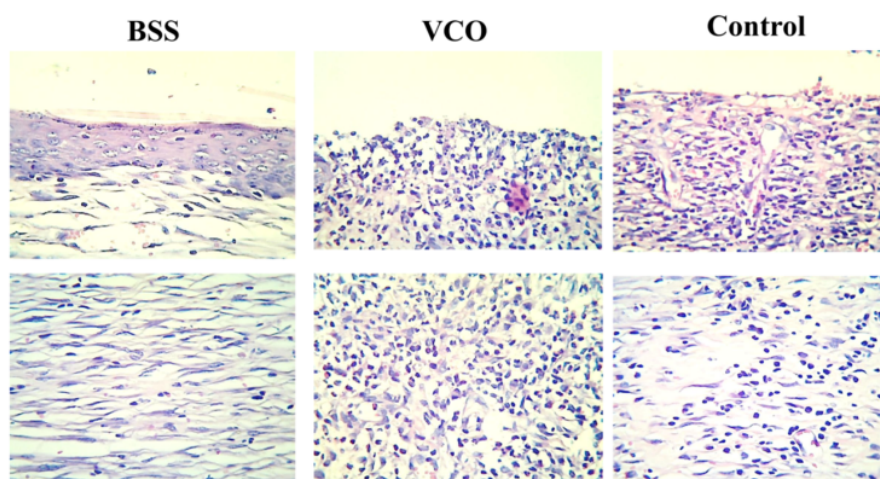


Figure 3. HE staining of epidermis (upper picture) and dermis (lower picture) in the BSS, VCO and control group on day 14.

4. Discussion

This study is the first comparing BSS and VCO effect in the healing of diabetic ulcers. Our study indicated that wounds treated with BSS healed faster compared with the ones treated with VCO, even compared with the ones treated with use of modern wound-dressing film dressing.

One characteristic of diabetic wounds is a prolonged inflammation due to local hypoxia and bacterial burden [17]. The reduction of inflammation in BSS might be due to the fact that BSS contain anti-inflammatory, antioxidant and antibacterial agents [4]. A recent study investigated ABSS composition, and found that BSS contains antioxidant such as polyphenols, tannin, saponins, and flavonoids [12]. In addition flavonoids have antibacterial activity. Indeed, the extract of banana stem has an antibacterial effect against *staphylococcus aureus* and *pseudomonas aeruginosa* [18].

In this study, the slough in VCO group was thicker than in the other groups. Slough reduction in the BSS and control group might be due to the fact that BSS and film dressing exerted an autolytic debridement, resulting in thinner slough compared with VCO group. In the VCO group, the slough was thicker from day 5 to day 14. The presence of slough causes more extensive inflammation into the surrounding skin, resulting in more tissue damage and accumulation of dead tissue in the wound bed [17]. This might be the reason why the inflammation in the VCO group was higher and more extensive than the other groups on day 14. Our study is not in agreement with a previous study revealing that wounds treated with VCO healed better compared with the ones in the control group [19]. This discrepancy might be due to the fact that in the previous study, the healing ability of a wound treated with VCO was compared with healing ability of an untreated wound, while in this study VCO healing effect was compared with the effect exerted by the modern wound-dressing used in the control group. Film dressing provides a moist environment in the wound, therefore promoting its re-epithelialization [20].

In this study, BSS also improved the granulation tissue, in agreement with previous studies showing that BSS can improve granulation tissue formation [21]. The formation of granulation tissue is better in BSS than in VCO group and control group. In our study, the level of fibroblast was higher than that in the control and VCO group. Fibroblasts represent the basic materials of collagen (mucopolysaccharides, aminoglysin acid and proline), which is important for granulation tissue formation [22]. A recent study suggested that the mechanism involved in the improvement of the granulation tissue formation may be due to the ability of BSS to increase PDGF-BB [21]. PDGF

stimulates fibroblast chemotaxis activity and proliferation, and the production of glycosaminoglycans. Glycosaminoglycans form a gel-like ground substance, in which the collagen fibers are embedded.

This study has one limitation. We investigated the wound healing effect only in term of inflammation, and re-epithelialization. However, our study is the first comparing BSS and VCO effect in the healing of diabetic ulcers consecutively and therefore the progression of wound healing was thoroughly observed.

Taken together, our study indicated that BSS was more effective in promoting the healing of diabetic ulcers, and therefore it might be a good candidate in the clinical usage. Nurse and clinician should use BSS over VCO to treat diabetic ulcers. A further study on human subject with diabetic ulcers is needed to confirm these findings.

5. Conclusions

This study compared the effect of BSS, VCO and modern dressing on wound healing of diabetic rats. Our results showed that the inflammation and the presence of slough were the least in BSS group compared with VCO and control group. The re-epithelialization was also most advanced in the BSS group. According to our evidences, BSS might be a good candidate for topical treatments of diabetic ulcer.

References

- [1] Shaw J E, Sicree R A and Zimmet P Z 2010 Global estimates of the prevalence of diabetes for 2010 and 2030 *Diabetes Res. Clin. Pract.* **87** 4–14
- [2] Khamaisi M and Balanson S 2017 Dysregulation of wound healing mechanisms in diabetes and the importance of negative pressure wound therapy (NPWT). *Diabetes. Metab. Res. Rev.* **33**
- [3] Haesler E, Watts R, Rice J C K 2016 Local resource botanicals used in wound care *Wound Pr. Res* **24** 84–90.
- [4] Imam M Z and Akter S 2011 Musa paradisiaca L . and Musa sapientum L . : A Phytochemical and Pharmacological Review Mohammad Zafar Imam and Saleha Akter *J. Appl. Pharm. Sci.* **01** 14–20
- [5] SHANMUGAVELU K G and RANGASWAMI G 1962 Tryptophan and Indole Compounds in Banana Ovaries *Nature* **194** 775
- [6] Lewis D A and Shaw G P 2001 A natural flavonoid and synthetic analogues protect the gastric mucosa from aspirin-induced erosions. *J. Nutr. Biochem.* **12** 95–100
- [7] Peumans W J, Zhang W, Barre A, Houles Astoul C, Balint-Kurti P J, Rovira P, Rouge P, May G D, Van Leuven F, Truffa-Bachi P and Van Damme E J 2000 Fruit-specific lectins from banana and plantain. *Planta* **211** 546–54
- [8] Priosoeryanto BP, Putriyanda N, AR L, V J, I W, BF P and R T 2007 The effect of ambon banana stem sap on the acceleration of wound healing process in mice (*Mus musculus albinus*) *J. Agric Rural Devp* 35–59
- [9] Sachs M, von Eichel J and Asskali F 2002 [Wound management with coconut oil in Indonesian folk medicine]. *Chirurg.* **73** 387–92
- [10] Marina A M, Man Y B C, Nazimah S A H and Amin I 2009 Antioxidant capacity and phenolic acids of virgin coconut oil. *Int. J. Food Sci. Nutr.* **60 Suppl 2** 114–23
- [11] Nevin K G and Rajamohan T 2010 Effect of topical application of virgin coconut oil on skin components and antioxidant status during dermal wound healing in young rats. *Skin Pharmacol. Physiol.* **23** 290–7
- [12] Hendrik Setia Budi, Indah Listiana Kriswandini and A D I 2015 Antioxidant activity test on ambonese banana stem sap (*Musa Dent. J.* **188** 188–92
- [13] Weremfo A and Adinortey M B 2011 Haemostatic Effect of the Stem Juice of *Musa paradisiaca* L . (*Musaceae*) in Guinea Pigs *Adv. Biol. Res. (Rennes)*. **5** 190–2
- [14] Sari Y, Hartono, Sutrisna E and Saryono 2019 The effect of short duration of electrical

- stimulation on wound healing in acute wound in a rat model *Wound Med.* **24** 36–44
- [15] Sari Y, Purnawan I, Kurniawan D W and Sutrisna E 2018 A Comparative Study of the Effects of Nigella sativa Oil Gel and Aloe Vera Gel on Wound Healing in Diabetic Rats. *J. evidence-based Integr. Med.* **23** 2515690X18772804
- [16] WS R 1997 ImageJ: image processing and analysis in Java
- [17] Sood A, Granick M S and Tomaselli N L 2014 Wound Dressings and Comparative Effectiveness Data *Adv. wound care* **3** 511–29
- [18] Amutha K and Selvakumari U 2016 Wound healing activity of methanolic stem extract of Musa paradisiaca Linn. (Banana) in Wistar albino rats. *Int. Wound J.* **13** 763–7
- [19] Soliman A M, Lin T S, Ghafar N A and Das S 2018 Virgin coconut oil and diabetic wound healing : histopathological and biochemical analysis *Eur. J. Anat* **22** 135–44
- [20] Diegelmann R F and Evans M C 2004 Wound healing: an overview of acute, fibrotic and delayed healing. *Front. Biosci.* **9** 283–9
- [21] Hs B, Il K and Sa S 2016 Ambonese banana stem sap (Musa paradisiaca var . sapientum) effect on PDGF-BB expressions and fibroblast proliferation in socket wound healing *Int. J. ChemTech Res.* **9** 558–64
- [22] Werner S and Grose R 2003 Regulation of wound healing by growth factors and cytokines. *Physiol. Rev.* **83** 835–70

A comparison of the effectiveness banana stem sap and virgin coconut oil on diabetic wound healing

ORIGINALITY REPORT

8%

SIMILARITY INDEX

8%

INTERNET SOURCES

%

PUBLICATIONS

%

STUDENT PAPERS

PRIMARY SOURCES

1

innovareacademics.in

Internet Source

5%

2

repository.usahidsolo.ac.id

Internet Source

3%

Exclude quotes On

Exclude bibliography On

Exclude matches < 3%