

A low-frequency of electrical stimulation improves wound healing

by Yunita Sari

Submission date: 10-Jul-2022 10:10AM (UTC+0700)

Submission ID: 1868506207

File name: A_low-frequency_of_electrical_stimulation_improves.pdf (1.62M)

Word count: 2980

Character count: 15164

PAPER • OPEN ACCESS**A low-frequency of electrical stimulation improves wound healing**

3

To cite this article: Yunita Sari *et al* 2019 *IOP Conf. Ser.: Earth Environ. Sci.* **255** 012014View the [article online](#) for updates and enhancements.**IOP | ebooks™**Bringing you innovative digital publishing with leading voices
to create your essential collection of books in STEM research.Start exploring the collection - download the first chapter of
every title for free.

A low-frequency of electrical stimulation improves wound healing

Yunita Sari^{1*}, Atyanti Isworo¹, Arif Setyo Upoyo¹, Akhyarul Anam¹, Hartono², Eman Sutrisna³, Saryono¹

¹Department of Nursing, Faculty of health sciences, Universitas Jenderal Soedirman, Purwokerto, 53123 Indonesia

²Department of Physics science, Faculty of sciences, Universitas Jenderal Soedirman, Purwokerto, 53123 Indonesia

³Department of Pharmacology, Faculty of medicine, Universitas Jenderal Soedirman, Purwokerto, 53123 Indonesia

*E-mail address: sasa.yunita@gmail.com/ yunita-ky@umin.ac.jp

Abstract. High frequency of electrical stimulation (ES) can cause patients to become uncomfortable. Therefore, it needs to use a low frequency of ES. However, the use of low frequency of ES (below 20 Hz) on wound healing is still unclear. Therefore, this study aimed to elucidate the effect of low frequency (10 Hz) of ES on wound healing. A wound with a diameter of one cm was created at the dorsal side of rats. The rats were divided into two groups; low frequency of electrical stimulation (LFES), and control group (without ES application). The application of ES was given for ten days. The wound size in the LFES group was smaller in LFES group compared to the control group. The intensity of polymorphonuclear neutrophils was lower in the LFES group, while the intensity of fibroblast was significantly higher in the LFES than in the control group. The formation of new epidermis (reepithelialisation) was faster in LFES group than in the control groups. Low frequency of ES (10 Hz) accelerated wound healing by reducing inflammation, improving the fibroblast intensity, and formation of new epidermis.

1. Introduction

The increase of the aging population will increase the pathological condition related to aging, such as the development of wound. The previous study revealed that up to 3% of aged people in United States (above 65 years old) developed a wound during a lifetime [1]. This number might be higher in the developing countries [1]. If these wounds are not treated well, it leads to the development of chronic wounds. Previous studies showed that the cost of treatment of chronic wounds was above \$50 billion per year [1-3]. Since the occurrence of the wounds will cause such impacts, therefore many researchers tried to find wound care therapies that can accelerate wound healing.

One of wound care therapies that can accelerate wound healing is electrical stimulation (ES). Electrical stimulation is the adjunct therapy that can deliver electrical currents to the targeted skin or tissue [4]. Electrical field will occur in our body when there is disruption in our skin [5]. This electrical field will help the epithelial migration during wound healing, resulting in faster wound closure [4]. Previous studies showed that electric stimulation could promote wound healing not only in acute wounds [6], but also in chronic wounds [7, 8].



Content from this work may be used under the terms of the Creative Commons Attribution 3.0 licence. Any further distribution of this work must maintain attribution to the author(s) and the title of the work, journal citation and DOI.

Published under licence by IOP Publishing Ltd

Most of previous studies related with electrical stimulation used the frequency above 50 Hz [9-13]. Franek et al [9] and Ahmad [10] showed that frequency of 100 Hz accelerated wound healing of pressure ulcers, while Houghton et al.[11] showed that 100 Hz improved wound healing of leg ulcers. Jancovic [12] studied that frequency of 1000 Hz improved the healing of leg ulcers, while Ud din et al. [13] used 60 Hz to improve dermal scar. All the above studies showed that the application of ES above 50 Hz could improve wound healing.

Our previous studies showed that the application of ES with frequency of 20 Hz could improve wound healing in chronic wound (diabetic ulcer) [14,15]. Our recent unpublished study also found that the best duration application of ES was 10 minutes a day. However, up to present, the effect of low frequency of ES below 20 Hz is still unclear. If the low frequency below 20 Hz of ES can also improve wound healing, it will be beneficial in the clinical setting, since the low application of ES may make the patients more comfortable during the application of ES. Previous study showed that application of high frequency of ES sometimes causes patients to become uncomfortable. Therefore, the purpose of this study was to investigate the wound healing of low frequency of ES on wound healing of acute wounds.

2. Method

2.1. Animal

Male Wistar rats at the age of 12 weeks were used to make rat model in this study. The animals body weight were 180-200 miligram. These rats were purchased from Purwokerto Muhammadiyah University, Purwokerto, Indonesia. The acclimatization period after purchasing was 7 days before treatment. The procedure of this study was approved by ethical committee, Faculty of Medicine, Universitas Jenderal Soedirman, Purwokerto, Indonesia.

2.2. Wounding method and treatment

After acclimatization for seven days, the hair of rats then was shaved. Before wounding procedure, the rats were injected with ketamile hydrochloride 90 mg/Kg of body weight. A wound with diameter of one cm was created at the dorsal region of rats. After wounding, the rats were divided into 2 groups, low frequency of electrical stimulation (LFES) and control group. LFES group received the low frequency of ES and standard treatment (covered with parafilm dressing), while control group only received standard treatment (covered with parafilm dressing). After wounding, the wounds in both groups were cleansed with normal saline solution (NaCl 0.9 %) and covered with parafilm dressing. Then, wound in the LFES group received ES application (10 Hz) for 10 minutes. The application of ES was based on previous studies [14,15]. The wounds in the LFES group were treated from day 0 to day 10 with ES. Every day the wounds in both groups were monitored and photographed. Any changes in the wounds were recorded. There was no rat died during wounding procedure and application of ES.

2.3. Hematoxylin and Eosin staining

The skin samples were taken on day 11. The skin tissue (wound tissue and normal tissue near the wound) were immediately immersed into formalin 10 %. The tissue was then processed in graded alcohol and xylene for Hematoxylin and Eosin staining (H and E). The tissue section was then observed under light microscope under magnification of 400X or 100X. The difference in the intensity of polymorphonuclear neutrophils (PMNs) and fibroblast was assessed based on the previous study [16].

2.4. Statistical analysis

Mann-Whitney-U test was used to assess the difference in the intensity of PMNs and fibroblast between LFES group and control group. The value of p less than 0.05 was considered significant. The statistical analysis used SPSS program version of 23.

3. Result and discussion

The result were discussed in three sections; they are wound bed appearance, histological analysis in epidermis and dermis layer, the intensity of PMNs and fibroblast, and reepithelialisation

3.1. Wound bed appearance

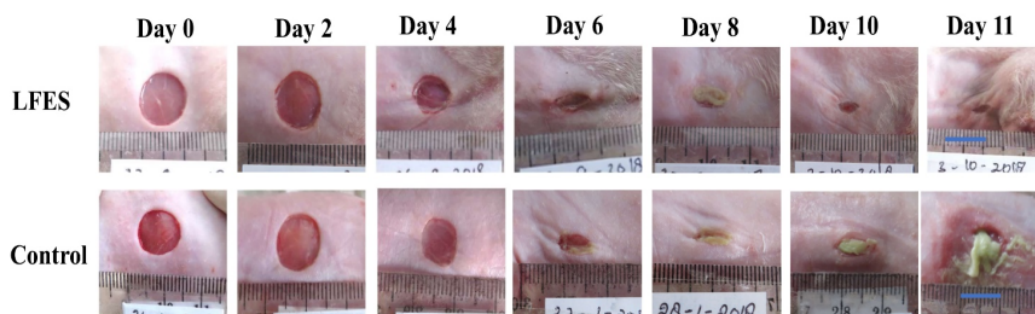


Figure 1. The appearance of the wound

On day 0, the wound bed color in the LFES group had a same color with wound in the control group. On day 2, the appearance of the wound bed in the LFES group still had similar appearance like in the control group. On day 4, the appearance of the wound bed in the LFES and control group was still similar, however the size of wound in the control group was wider compared with LFES group. On day 8, the slough (necrotic tissue with yellow color) could be observed in both groups, however, the slough in the control group was larger compared with LFES group. On day 10, the slough was not present in the LFES group, while it was still present in the control group. On day 11, the wound in the LFES group was almost healed, and already covered with new epithelial cells, however, wound in the control group was still covered with slough. Moreover, the surrounding tissue was also red in the control group, indicating extensive inflammation into surrounding tissue. The exudate was not present on day 11 in the LFES group, however, the exudate in the control group was still present and the color was purulent.

Based on figure 1, the wound in the control group was still covered with slough when the wound in the LFES group was already covered with granulation tissue. The presence of slough indicates the reduction of blood flow in the wound [17]. The reduction of blood flow will cause accumulation of dead cells in the wound bed. In the LFES group, the slough was not present on day 10, it indicated the application of LFES can improve the blood flow to the wounds, resulting in the removal of the slough from the wound bed.

On day 11, the wound in the LFES group had no exudate while wound in the control group had a purulent exudate. Moreover, there was a redness in the surrounding tissue. It might indicate that there was increased of bacterial burden in the control group, while there was reduction of bacterial burden in the LFES group. The reduction of the bacterial burden in the LFES group indicated that the application of low frequency of ES reduced the number of bacteria in the wounds. Our study corresponds with previous study that showed the application of ES could reduce the bacterial burden in the wounds. [18]. The type of bacteria could be inhibited or destroyed by ES were *Staphylococcus epidermidis*, *Staphylococcus aureus*, *P. aeruginosa*, *E. coli*, and *Klebsiella* [19,20]

3.2. Histological analysis in epidermis and dermis layer

The result of the histological analysis in the epidermis layer is shown in figure 2. The inflammatory cells was indicated by the cells which have blue color in the tissue. The inflammatory cells was rare in the epidermis layer of LFES group on day 11, however the inflammation in the control group was still

enormous. In the control group, slough was covered all part of the epidermis layer, while there was no necrotic tissue in the epidermis layer of LFES group. Figure 3 showed the histological appearance of dermis on day 11. Similar with the findings in the epidermis, the figure showed that the number of inflammatory cells in the LFES group in dermis was also less compared to the control group.

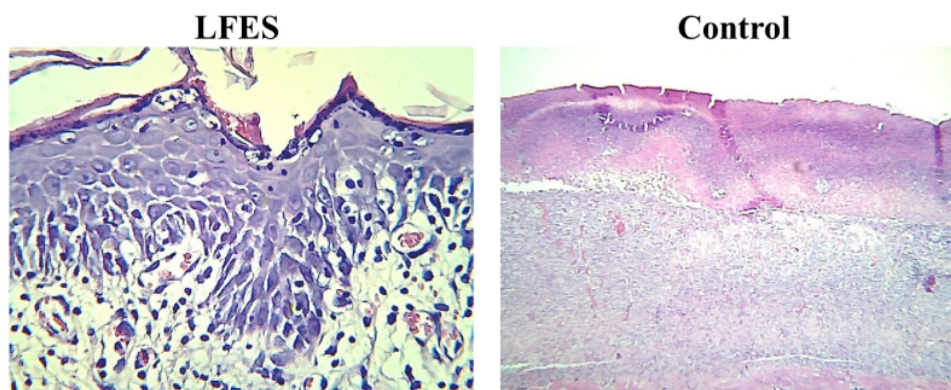


Figure 2. H and E staining of the epidermis layer of LFES group and control group (magnification of 400 X)

The presence of slough in the epidermis and dermis layer in the control group can cause spreading inflammation into the healthy tissue. Previous studies showed that inflammatory cells released reactive oxygen species that could increase oxidative stress in tissue [21]. The increase of oxidative stress would also increase the number of inflammatory cells in the tissue. In the LFES group, there was improvement of blood flow and therefore the production of ROS might be reduced, resulting in reduction of inflammation.

In the LFES group, the application of frequency under 20 Hz of ES reduced the migration of inflammatory cells (neutrophil and macrophage) to the wound site. Excessive migration of inflammatory cells will cause extensive inflammation in the wound site. Our study was in accordance with previous study that revealed the application of ES reduced the inflammation of the wounds [22]. Another mechanism of the reduction of PMNs in this study might also be involved. A previous study showed that ES can also caused the inflammation phase become shorter than wound not treated with ES since ES could reduce the number of CD3+ cells.[22]

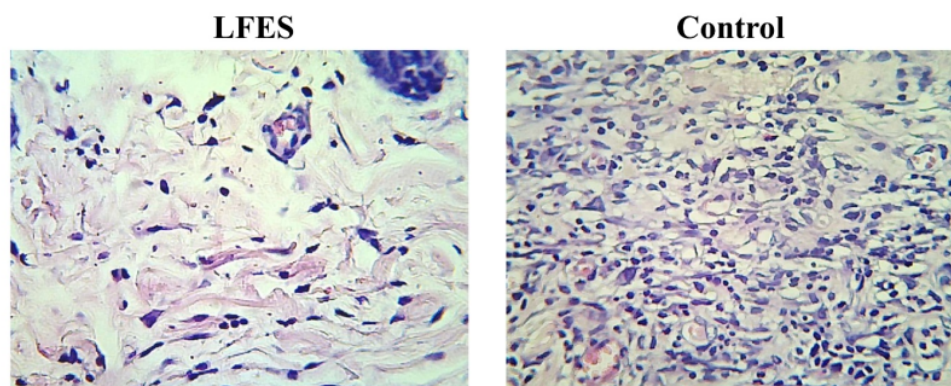


Figure 3. H and E staining of the epidermis layer of LFES group and control group (magnification of 400 X)

3.3. The intensity of PMNs and fibroblast

The intensity of PMNs and fibroblast on day 11 is shown in table 1. Table 1 shows that the intensity of PMNs in the LFES group was significantly lower ($p=0.014$) in the LFES group compared with control group. The intensity of fibroblast in the LFES group was significantly higher in the LFES group ($p=0.018$) compared with control group.

The improvement of the granulation tissue in the LFES group might due to the increase of the fibroblast in the LFES group. Fibroblast is mayor cells that deposit or produce granulation tissue. During wound healing process, fibroblast will proliferate and migrate to the injury site to produce extracellular matrix which act as a scaffolding during regeneration of tissue [23]. Fibroblast can also differentiate to become myofibroblast, which have a key in wound contraction process [24]. Fibroblast also has a critical role during wound angiogenesis, since fibroblast can produce and release vascular endothelial growth factor which has a role as proangiogenic mediators [25]

Table 1. The intensity of PMNs and fibroblast on day 11

Groups	PMNs	Fibroblast
LFES	2*	3*
Control	3.5	2

Values represent the median score. Scores can range from 0 4 absent (1 = occasional appearance; 2 = moderate appearance; 3 = abundant appearance; 4 = very abundant apperance). * $p < 0.05$

3.4. Reepithelialization

Figure 4 showed the reepithelialization in the LFES group and control group. The figure 4 showed that the wound reepithelialization in LFES group was longer than in the control group. The center of the wound in the LFES group was already covered with new epithelial cells, while the epidermis in the control group was not covered with new epithelial cells yet.

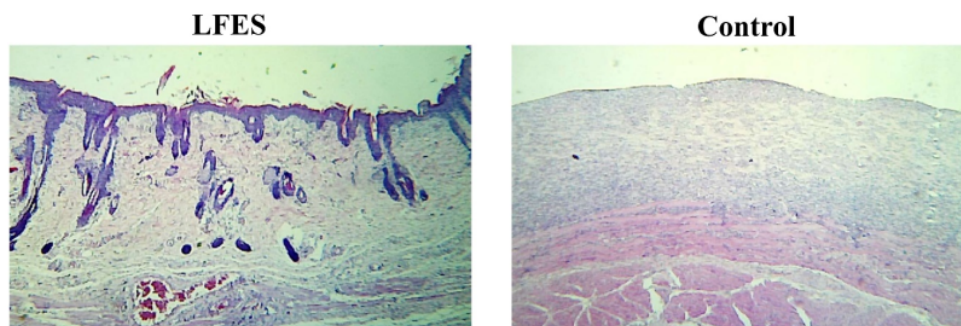


Figure 4. Repithelialization between LFES group and control group (magnification of 100 X)

The disruption of the reepithelialisation in the control group might be due to the extensive inflammation in the epidermis. The extensive inflammatory cells can increase the oxidative stress that can destroy the healthy tissue in surrounding areas. The ability of LFES to accelerate the reepithelialisation might be due to the ability of ES to improve epithelial migration [25]. Our study was according to the previous study that revealed ES above 100 Hz improved the keratinocytes migration. Surprisingly, our study showed that the frequency of 10 Hz also improved wound reepithelialisation. Previous study showed that the improvement of reepithelialisation in LFES group might be due to the ability of ES in increasing of Collagen IV, which is important for proliferation of keratinocytes.

4. Conclusion

The application of low frequency of ES (10 Hz) reduced the presence of slough, exudate, PMNs and increased fibroblast and improved reepithelialization. Based on this study, it is suggested to use low frequency of ES (10 Hz) to treat acute wound in the clinical setting.

Acknowledgement

We thank the ministry of research, technology and higher education for supporting this study through a grant of Penelitian Unggulan perguruan Tinggi.

References

- [1] Sen CK, Gordillo GM, Roy S, Kirsner R, Lambert L, Hunt TK, Gottrup F, Gurtner GC, Longaker MT 2009 **Wound Repair Regen** 17 763-771
- [2] Driver VR, Fabbi M, Lavery LA, Gibbons G 2010 *J Vasc Surg* 52 17S-22S.
- [3] Kuhn BA and Coulter SJ 1992 *Nurs Econ* 10 353-359
- [4] Kloth LC. 2005 *Int J Low Extrem Wounds* 4 23-44.
- [5] Foulds IS and Barker AT 1983 *Br J Dermatol* 109 515-522.
- [6] Petrofsky J, Lawson D, Prowse M, Suh HJ 2008 *J Med Eng Technol* 32 485-497.
- [7] Burdge JJ, Hartman JF, Wright ML 2009 *Ostomy Wound Manage* 55:30-38.
- [8] Houghton PE, Campbell KE, Fraser CH, Harris C, Keast DH, Potter PJ, Hayes KC, Woodbury MG 2010 *Arch Phys Med Rehabil* 91 669-678.
- [9] Franek A, Kostur R, Polak A, Taradaj J, Szlachta Z, Blaszcak E, Dolibog P, Koczy B, Kucio C. 2012 *Ostomy Wound Manage* 58 30-44.
- [10] Ahmad ET 2008 *Ann Burns Fire Disasters* 2008 21:124-128.
- [11] Houghton PE, Kincaid CB, Lovell M, Campbell KE, Keast DH, Woodbury MG, Harris KA 2003 *Phys Ther* 83:17-28.

- [12] Jankovic A and Binic I 2008 *Arch Dermatol Res* **300** 377–383.
- [13] Ud-Din S, Giddings Dip P, Colthurst J, Whiteside S, Morris J, Bayat A 2013 *Wounds a Compend Clin Res Pract* **25** 212–224.
- [14] Sari Y, Saryono, Sutrisna E, Hartono 2017 *Jurnal Ners*, **12** 253-260.
- [15] Sari, Y., Sutrisna E and H. 2017 The 3rd International Conference on Nursing (ICON) (Malang: UMM Press) p 546-551
- [16] Wright JB, Lam K, Buret AG, Olson ME, Burrell RE 2002 *Wound Repair Regen* **10** 141–51.
- [17] Grey JE, Enoch S, Harding KG. 2006 *BMJ* **332** :285–288
- [18] Asadi MR and Torkaman G. 2014 **3** 91–97.
- [19] Szuminsky NJ, Albers AC, Unger P, Eddy JG 1994 *Phys Ther* **74** 660–667.
- [20] Liu WK, Brown MR, Elliott TS. 1997 *J Antimicrob Chemother* **39** 687–695.
- [21] McCord JM. 1985 *N Engl J Med* **312** 159–163.
- [22] Sebastian A, Syed F, Perry D, Balamurugan V, Colthurst J, Chaudhry IH, Bayat A 2011 *Wound Repair Regen* **19** 693–708
- [23] Midwood KS, Williams LV, Schwarzbauer JE 2004 *Int J Biochem Cell Biol* **36** 1031–1037.
- [24] Gabbiani G 2003 *J Pathol* **200**:500–503.
- [25] Kendall RT, Feghali-Bostwick CA. Fibroblasts in fibrosis: novel roles and mediators 2014 *Front Pharmacol* **27** 123.

A low-frequency of electrical stimulation improves wound healing

ORIGINALITY REPORT

13%

SIMILARITY INDEX

11%

INTERNET SOURCES

10%

PUBLICATIONS

6%

STUDENT PAPERS

PRIMARY SOURCES

1	www.pmrslab.cn Internet Source	3%
2	repository.istn.ac.id Internet Source	2%
3	istina.ipmnet.ru Internet Source	1%
4	innovareacademics.in Internet Source	1%
5	Alexander Reyzelman. "Clinical effectiveness of an acellular dermal regenerative tissue matrix compared to standard wound management in healing diabetic foot ulcers: a prospective, randomised, multicentre study", International Wound Journal, 06/2009 Publication	1%
6	Paulo Roberto Lopes Nalesso, Weiguang Wang, Yanhao Hou, Leonardo Bagne et al. "In vivo investigation of 3D printed	1%

polycaprolactone/graphene electro-active bone scaffolds", Bioprinting, 2021

Publication

7	www.mdpi.com Internet Source	1 %
8	bmccresnotes.biomedcentral.com Internet Source	<1 %
9	www.j3.jstage.jst.go.jp Internet Source	<1 %
10	pertambangan.fst.uinjkt.ac.id Internet Source	<1 %
11	www.ejh.it Internet Source	<1 %
12	www.sciencepub.net Internet Source	<1 %
13	www.pubmedcentral.nih.gov Internet Source	<1 %
14	Jieyu Zhang, Koon Gee Neoh, En - Tang Kang. "Electrical stimulation of adipose - derived mesenchymal stem cells and endothelial cells co - cultured in a conductive scaffold for potential orthopaedic applications", Journal of Tissue Engineering and Regenerative Medicine, 2017 Publication	<1 %

15

Internet Source

<1 %

16

rsds.org

Internet Source

<1 %

17

Submitted to University of Lancaster

Student Paper

<1 %

Exclude quotes On

Exclude matches Off

Exclude bibliography On