

on_Skin_Tissue_of_Psoriasis_Mice_Model_An_Experimental_Study.pdf

by

Submission date: 11-Feb-2022 04:33PM (UTC+0700)







Submission ID: 1759961531

File name: on_Skin_Tissue_of_Psoriasis_Mice_Model_An_Experimental_Study.pdf (1.1M)

Word count: 3780

Character count: 20746

Reversible Imiquimod Effects on Skin Tissue of Psoriasis Mice Model: An Experimental Study

Thianti Sylviningrum¹, Afifah², Dody Novrial³, Brian Wasita⁴, Bambang Purwanto⁵,
Harijono K. Sentono⁶

¹ Doctoral Degree of Medical Science Programme, Faculty of Medicine, Universitas Sebelas Maret, Surakarta, Indonesia

² Department of Pharmacology, Faculty of Medicine, Universitas Jenderal Soedirman, Purwokerto, Indonesia

³ Department of Anatomical Pathology, Faculty of Medicine, Universitas Jenderal Soedirman, Purwokerto, Indonesia

⁴ Department of Anatomical Pathology, Faculty of Medicine, Universitas Sebelas Maret, Surakarta, Indonesia

⁵ Department of Internal Medicine, Faculty of Medicine, Universitas Sebelas Maret, Surakarta, Indonesia

⁶ Department of Dermatology and Venereology, Faculty of Medicine, Universitas Sebelas Maret, Surakarta, Indonesia

Keywords: Imiquimod, skin, mice model, psoriasis.


Abstract: Psoriasis is an incurable inflammatory disease with erythematous, scaly, and thick skin. Imiquimod (IMQ)-induced psoriasis mice have been widely used since it may resemble psoriasis human. Imiquimod effects on development, peak, and resolution of mice skin are crucial. Thus, this study aims at evaluating IMQ effects on psoriasis mice model skin tissue changes. Twenty-seven female Balb/c mice 8-11 weeks, 20-25 grams body weight (BW) were randomized equally into control (A) and experimental groups (B,C). Over 25 grams BW mice after acclimatization were excluded. The mice had shaved their back then topically applied emollient (A) and IMQ (B,C) for 7 consecutive days. On day 8 (A,B) and 15 (C), mice were terminated and back skin harvested for histopathological examination. Psoriasis Area Severity Index (PASI) and Baker's scores were used to measure macroscopic and microscopic skin changes. All groups score differences were assessed using Kruskal Wallis then Mann Whitney tests. Skin changes gradually appeared from day 2 to 7 of IMQ applications and faded after 2 days IMQ discontinuation. On day 7, all mice showed means of PASI scores 0(A); 9,00±2,69(B); 8,11±1,62(C) with significant differences between experimental to control groups ($p = 0.00$). Means of PASI scores from mice group C on day 15 showed similar to group A ($p = 0.10$). Means of Baker's scores from all groups were 1,16±0,25(A); 3,33±1,25(B); 1,39±0,22(C) and group B mice showed different significant scores from others ($p = 0.00$). As conclusion, the IMQ showed a reversible effect on skin tissue changes in psoriasis mice model. The abstract should summarize the contents of the paper and should contain at least 70 and at most 200 words. It should be set in 9-point font size, justified and should have a hanging indent of 2-centimeter. There should be a space before of 12-point and after of 30-point.


1 INTRODUCTION


Psoriasis is an autoimmune disease characterized by the erythematous plaque covered by the thick, silvery, and scaly skin lesions with the chronic inflammatory background (Boehncke & Schön, 2015). The disease has complex pathophysiological pathways involving


the interactions of multi-genetic and environmental factors. Psoriatic patients who have skin and/or systemic manifestations may decrease their quality of life, and need long-term treatment possibly associated with higher side effects and lower compliance (Belinchón et al., 2016). World Health Organization (WHO) reported that there were approximately 2% of psoriasis patients throughout the world and tended


 <https://orcid.org/0000-0003-0349-0087>

 <https://orcid.org/0000-0002-5703-7061>

 <https://orcid.org/0000-0002-3807-852X>

 <https://orcid.org/0000-0002-5501-3541>


 <https://orcid.org/0000-0003-3389-9043>

 <https://orcid.org/0000-0001-5338-6005>

260

Sylviningrum, T., Afifah, A., Novrial, D., Wasita, B., Purwanto, B. and Sentono, H.

Reversible Imiquimod Effects on Skin Tissue of Psoriasis Mice Model: An Experimental Study.

 10.5220/0010491002600266

In Proceedings of the 1st Jenderal Soedirman International Medical Conference in conjunction with the 5th Annual Scientific Meeting (Temiinas) Consortium of Biomedical Science Indonesia

(JIMC 2020), pages 260-266

ISBN: 978-989-758-499-2

Copyright © 2021 by SCITEPRESS – Science and Technology Publications, Ltd. All rights reserved

increasing in the last 20 years (WHO, 2016). This condition indicates that more studies are required to investigate the pathways involved in the development of psoriasis and treatment method associated with a good response and minimum side effects.

Studies on pathophysiological and drug development in human psoriasis patients may face the ethical problems. Thus, psoriasis animal model is preferable. Imiquimod (IMQ)-induced psoriasis mouse model is the most widely used research instrument because it is inexpensive, easy to perform, and immediately induce the acute inflammatory process resembles human psoriasis. This procedure may also trigger the psoriasis skin manifestations, such as erythematous, skin hyperplasia, and scaling.

The pathognomonic histopathological changes of human psoriasis were also found, including munro abscess, acanthosis, keratinocyte hyperplasia, parakeratosis (Hawkes et al., 2017). The application of 62.5mg imiquimod daily may induce the psoriasis skin lesions on the back-shaved Balb/c mice through their activation of Interleukin (IL)-23/IL-17 axis (Bocheńska et al., 2017). The previous studies showed that IMQ might affect a rapid, temporary, and reversible inflammation on the human skin (Van der Kolk et al., 2018), yet the information on the duration of inflammation development process during the application of IMQ on mice was various and limited. The duration of inflammation process in IMQ-induced psoriasis mouse model is essential for the momentum to do the treatment procedures for new drug development.

2 MATERIALS AND METHODS

This study is an experiment study with posttest-only control design that held in February to April 2020 in Pharmacology Department, Medical Faculty of Universitas Jenderal Soedirman, Central Java, Indonesia. Twenty-seven female Balb/c mice aged 8-11 weeks and weighed 20-25 grams were divided into three groups: control group (A), first treatment group (B), and second treatment group (C) consisting of 9 mice per group. The female Balb/c mice were obtained from the Department of Pharmacology, Faculty of Medicine, Universitas Gadjah Mada, Indonesia.

All mice underwent 7-day acclimatization period and were under-maintained in 12-12 hour light and dark cycle with ad libitum food and drink. After the acclimatization period, all mice were then anesthetized with 0.1 ml intramuscular injection per 10 gram BW, 80mg/kgBW with ketamine cocktail;

12.5 mg/kg BW with xylazine cocktail; 3mg/kg BW with acepromazine cocktail (Vertebrate Animal Research, 2020). After anesthetized, 2x2 cm² of all mice's back was shaved using an animal shaver and applied with the depilatory cream Veet®. For the next consecutive 7 days, each mouse in group A was applied with 62.5 mg Noroid cream® (Soho Global Health, Indonesia) on the shaved back skin, and 62.5mg of Aldara cream® (3M Pharmacy, United Kingdom) that contains 5% imiquimod was applied on the shaved back skin of each mouse in group B and C. On day 8, the PASI scores of mice in all groups were evaluated and terminated using the cervical dislocation for those mice in group A and B followed by back skin tissue harvesting. This step was repeated on day 15 for mice in group C.

All skin tissues underwent a histopathological examination using the hematoxylin and eosin staining. The components of PASI scores for mice were interpreted as erythematous (0-4), scaling (0-4), thickness (0-4) with the total score of 0-12 by 2 certified dermatologists (Luo et al., 2016). To minimize the subjectivity in evaluating the erythema, the erythema level was scored based on color, 0 = no color changes; 1 = light pink; 2 = pink; 3 = red; and 4 = dark red/violet. The scaling was scored based on the observance, while the skin thickness was evaluated by the histopathological examination. Two pathologists evaluated and scored the histopathological examination results using Baker's scoring system as presented in Table 1 (Baker et al., 1992).

Table 1. Baker's scoring system

Items		Score
Keratin	Munro Abscess	2.0
	Hyperkeratosis	0.5
Epidermis	Parakeratosis	1.0
	Thinning above papillae	0.5
	Lengthening and clubbing of rete ridges	1.5
	Acanthosis	0.5
	Lack of granular layer	1.0
Dermis	Lymphocytic infiltrate	
	Mild	0.5
	Moderate	1.0
	Marked	2.0
	Papillary congestion	0.5

Kruskal Wallis test and Mann Whitney test were used to measure the difference between PASI and Baker's scores of the groups. The p value of < 0.05

was considered having a significant difference between variables. This research was approved by the Health Research Committee, Faculty of Medicine, Universitas Jendral Soedirman Number: Ref: 03IIIGPMII/2020.

3 RESULTS

All mice included in this study have completed with the acclimatization period. The mice were treated in accordance with the procedure mentioned in the method section. By the end of day 7, all mice in group B and C had psoriasis-like skin inflammation lesions, but those in group A did not. The mice in group C had the normal skin after 7-day application discontinuation of IMQ (Figure 1).

During the application of IMQ on the mice in group B and C, there was an increasing erythema score from day 2, that is, the preceding scaling and skin thickness manifested starting from day 3. On day 7 as the last application of IMQ on the mice in groups B and C resulted in the highest erythema, scaling, and thickness scores. In group C mice, there was a gradual decrease in skin scaling and thickness 1 day after IMQ exposure discontinuation. Meanwhile the erythema score began to subside on day 2 after the last application of IMQ. All PASI score components had returned to 0 score on day 13 (Figure 2). The mice in group A did not show any changes in their skin erythema, scaling, and thickness during the study.

In this study, the PASI mean scores in all groups were respectively 0 (group A); 9.00 ± 2.69 (group B); 8.11 ± 1.62 (group C on day 7); and 0 for group C on day 14. The Kruskal Wallis test result showed the significant difference of PASI scores on day 7 among all groups ($p = 0.000$). Post hoc study showed the significant difference of PASI scores between groups A and B, groups A and C on day 7, group B and C on day 14, also groups C on day 7 and day 14 ($p = 0.000$). Meanwhile, no significant difference in PASI scores was found between those in group B and C on day 7 ($p = 0.465$), also those in group A and C on day 14 ($p = 1.000$).

The skin tissue was stained using hematoxylin and eosin further scored using Baker's system. Mice in group A and C showed normal epidermis and dermis layers. Psoriasis-like histopathological changes were found in the mice in group B, such as parakeratosis, Munro microabscess, acanthosis, thinning above papillae, neutrophils and lymphocytes infiltrate, and papillary congestions (Figure 3). The following data were mean of Baker's scores \pm standard deviation in group A, B, and C; 1.16 ± 0.25 ;

3.33 ± 1.25 ; and 1.39 ± 0.22 . Baker's scoring system used in this study found significant differences among all groups ($p = 0.000$). Further tests showed the statistically significant differences of the mice in group A and B ($p = 0.000$); group B and C ($p = 0.001$), yet not between mice in group A and C ($p = 0.065$).

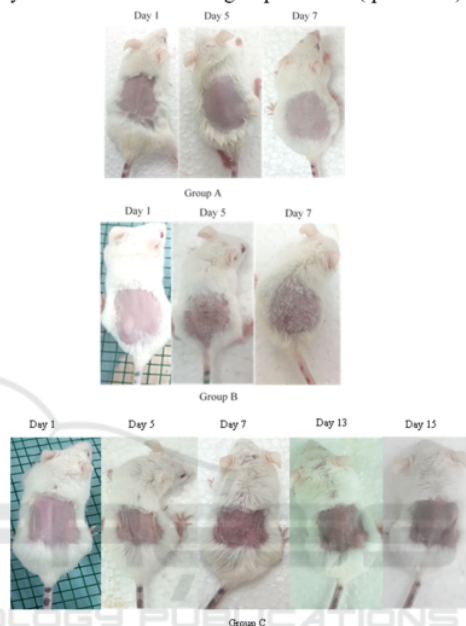


Figure 1. Psoriasis-like skin lesion developed by the mice in group B and C after the application 5% imiquimod cream (Aldara®), while mice in group A had no changes in their skin appearances. This psoriasis-like skin manifestation was gradually decreased after the application discontinuation of 5% imiquimod cream in group C.

4 DISCUSSIONS

Psoriasis is an inflammatory disease that may be induced by multifactor, including drugs. Imiquimod is known as one of the drugs that may induce psoriasis in humans (Balak et al., 2017), meanwhile, IMQ application in mice could trigger psoriasis-like skin inflammation (Bocheńska et al., 2017). The use of IMQ to induce psoriasis mice may provide the benefits of investigating the pathogenesis and developing new drugs for psoriasis.

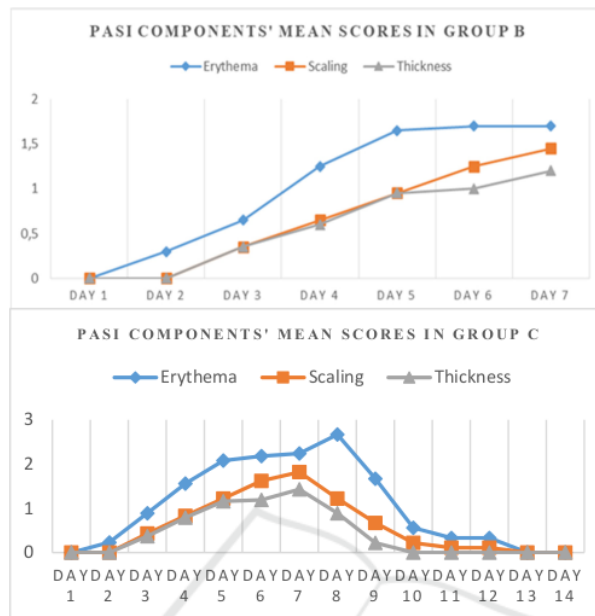


Figure 2. Progressively increasing mean of PASI scores components in groups B and C in the 7-day application of IMQ were as the culmination point. In the mice of group C, these PASI score components also showed gradually after discontinuation of IMQ applications.

In this study, psoriasis-like skin inflammation induced by IMQ in mice was successful, evidenced by the mean of PASI scores of mice in treatment groups significantly higher than control one. The results of this study showed similar findings from Luo et al. (2016) that stated IMQ was a strong inducer of psoriasiform changes in the mice skin tissue.⁸ The IMQ exposures will bond to the TLR7 on the surface of keratinocytes (Li et al., 2013), macrophages, and plasmacytoid dendritic cells⁵ followed by NF- κ B, mitogen-activated kinase protein, and activations of the inflammatory signaling pathways (Ma et al., 2020).

The IMQ exposure may cause the maturation of dendritic cells and the mature ones will release IL-23. The IL-23 may induce the differentiation and activation of Th17 cells (Ueyama et al., 2014). The activated Th17 cells will continue releasing inflammatory cytokines and the chemo-attractants that possibly causing the neutrophil migrations from the dermal vascular to the epidermal layers, and induce the keratinocyte cells to produce antimicrobial peptides (AMPs) including cathelicidin. In psoriasis, cathelicidin may induce inflammation by activating immune cells via multiple pathways (Takahashi et al.,

2020). All of these processes may produce gradual and prolonged inflammation in psoriasis (Kelh  la et al., 2014). The skin tissue inflammation in mice induced by the IMQ has gradually appeared. In this study, the inflammation signs were initiated by erythematous from day 2, followed by skin scaling and thickness that visible from day 3. These skin inflammation changes also showed disappeared sequentially after discontinuation of IMQ exposures. Unlike erythematous score that showed reduced later, skin scaling and thickness disappeared earlier started from day 1 after IMQ exposure cessation. These gradual changes could be explained by immunological circuits involving immune cells as described above. Therefore, it is important to determine the peak occurring inflammation to become the point where the Previous studies showed that psoriasis histopathological features may have similarities with chronic dermatitis (Ghasemi Basir et al., 2018) and other psoriasiform dermatitis (Chanadanwale et al., 2015). Previous study mentioned that different mice strains that induced with IMQ may give distinct responses that correspond to other human skin disorders such as wounds or infections (Swindell et al., 2017). Therefore, a

histopathological examination should be done to determine psoriasiform changes apart from clinical features evaluation in psoriasis-like inflammation mice. Based on human psoriasis and psoriasiform dermatitis skin biopsies, a prior study mentioned that

acanthosis, parakeratosis, hyperkeratosis, Munro microabscess, dilated blood vessels, and inflammatory infiltrates in the upper dermis including neutrophils and lymphocytes consistent with psoriasis (Chanadanwale et al., 2015).

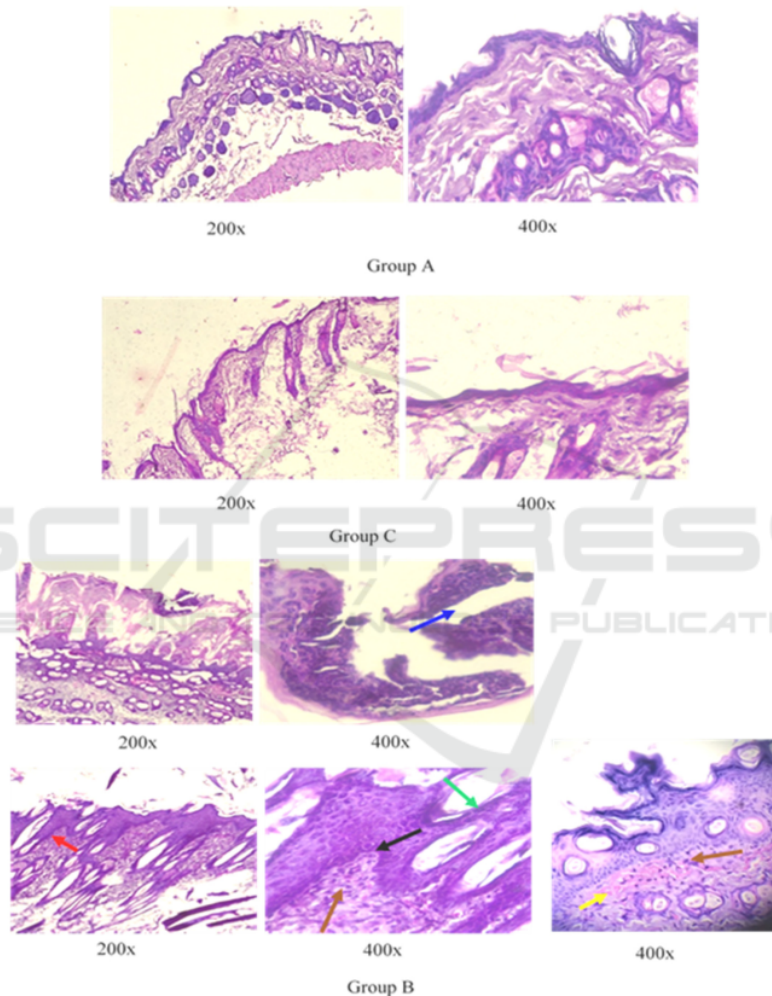


Figure 3. Histopathological changes was not found in the mice in group A and C. Mice in group B showed the Munro abscess (blue arrow), acanthosis (red arrow), parakeratosis (green arrow), thinning above papillae (black arrow), mild-moderate lymphocyte infiltration (brown arrow), and papillary congestion (yellow arrow) which was pathognomonic to the psoriasis.

In this present study, these histopathological features are also found in the skin tissue of group B mice. The mice which were not applied with IMQ (group A) or 7-day application discontinuation of

IMQ (group C) showed that the histopathological images mimicking psoriasis were not found. The mean of Baker's score 3.33 ± 1.25 in the group B mice significantly differed from other groups. These

outcomes proved that imiquimod induction in mice for 7 days succeeded in providing the same psoriasiform histopathological features as those found in human psoriasis. The results of this study are consistent with those conducted by Luo et al. (2016), that the repeated applications of IMQ could cause changes in the histopathological features resembling psoriasis.⁸ These histopathological changes could be initiated by skin irritation after application of IMQ following the mice back shave that leads to the increase of infiltrating lymphocytes, monocytes, and dermal dendritic cells including plasmacytoid dendritic cells (Luo et al., 2016; Ueyama et al., 2014; Chiricozzi et al., 2018).

Furthermore, imiquimod induced maturation of plasmacytoid dendritic cells into activated myeloid dendritic cells which acted as the main source of IL-23 (Giolomoni et al., 2017). The increase of IL-23 will direct Th17 to release IL-17 and IL-22 that trigger epidermal hyperplasia, acanthosis, and parakeratosis.²¹ Hereafter, IL-17, and IL-22 also induce the keratinocytes to produce IL-8 and AMPs as chemoattractants for neutrophils migration from dermal vascular to epidermis layers which may appear as the Munro/Kogoj microabscess (Luo et al., 2016; Kelh  la et al., 2014; Chiricozzi et al., 2018; Moos et al., 2019). These steps of the inflammation process in psoriasis may elucidate the histopathological changes induced by IMQ in the skin of mice.

This study also indicated that the mice skin tissues exposed to IMQ may cause the temporary induction of psoriasiform histopathological changes. The limitation of this study is we cannot identify the stages of psoriasiform histopathological changes during IMQ exposure or discontinuation, unlike the clinical manifestation of gradual inflammation changes that can be observed and scored. Nevertheless, to the best of our knowledge, this is the first study that shows the inflammatory effects of IMQ in Balb/C female mice are temporary and the period for these inflammatory signs subsided. The duration of IMQ-induced inflammation in psoriasis mice model is useful for further research to identify pathogenesis and drug development for psoriasis.

5 CONCLUSIONS

The IMQ may induce reversible acute inflammation with clinical and histopathological changes resembling psoriasis in humans as treated on the female Balb/c mice.

ACKNOWLEDGMENTS

We thank the following individuals, namely Lantip Rujito who help us to write this article, Shinta Prima Ardinas and Nirwan for their proficiencies, experiences, and assistance throughout laboratory aspects of our study.

REFERENCES

- Baker, B.S., Brent, L., Valdimarsson, H., Powles, A.V., al-Imara, L., Walker, M., et al. 1992. Is epidermal cell proliferation in psoriatic skin grafts on nude mice driven by T-cell derived cytokines? *Br J Dermatol.*, 126(2), 105-110. doi: 10.1111/j.1365-2133.1992.tb07805.x.
- Balak, D.M.W., Hajdarbegovic, E., 2017. Drug-induced psoriasis: clinical perspectives. *Psoriasis (Auckl.)*, 7, 87-94. doi: 10.2147/PTT.S126727.
- Belinch  n, I., Rivera, R., Blanch, C., Comellas, M., Liz  n, L., 2016. Adherence, satisfaction and preferences for treatment in patients with psoriasis in the European Union: a systematic review of the literature. *Patient Prefer Adherence*, 10, 2357-2367. doi: 10.2147/PPA.S117006.
- Boche  ska, K., Smoli  ska, E., Moskot, M., Jak  bkiewicz-Banecka, J., Gabig-Cimi  ska, M., 2017. Models in the Research Process of Psoriasis. *Int J Mol Sci.*, 18(12), 2514. doi: 10.3390/ijms18122514.
- Boehncke, W.H., Sch  n, M.P., 2015. Psoriasis. *Lancet*, 386(9997), 983-994. doi: 10.1016/S0140-6736(14)61909-7.
- Chanadanwale, S.S., Panicker, N.K., Kulkarni, S.P., Shah, K.R., Kumar, H., Sharma, Y.K., et al., 2015. Morphometry analysis of psoriasis and psoriasiform dermatitis: A retrospective study of 50 cases. *Med J DY Patil Univ.*, 8, 43-47. doi: 10.4103/0975-2870.148843.
- Chiricozzi, A., Romanelli, P., Volpe, E., Borsellino, G., Romanelli, M., 2018. Scanning the Immunopathogenesis of Psoriasis. *Int J Mol Sci.*, 19(1), 179. doi: 10.3390/ijms19010179.
- Ghasemi Basir, H.R., Alirezai, P., Hamian, Z., Khanlarzadeh, E., 2018. Are quantitative histopathologic criteria capable of differentiating psoriasis from chronic dermatitis?, *Clin Cosmet Investig Dermatol.*, 11, 239-244. doi: 10.2147/CCID.S160697.
- Giolomoni, G., Strohal, R., Puig, L., Bachelez, H., Barker, J., Boehncke, W.H., et al., 2017. The role of IL-23 and the IL-23/Th 17 immune axis in the pathogenesis and treatment of psoriasis. *J Eur Acad Dermatol Venereol.*, 31(10), 1616-1626. doi: 10.1111/jdv.14433.
- Hawkes, J.E., Gudjonsson, J.E., Ward, N.L., 2017. The Snowballing Literature on Imiquimod-Induced Skin Inflammation in Mice: A Critical Appraisal. *J Invest Dermatol.*, 137(3), 546-549. doi: 10.1016/j.jid.2016.10.024.

- Kelhlälä, H.L., Palatsi, R., Fyhrquist, N., Lehtimäki, S., Väyrynen, J.P., Kallioinen, M., et al. 2014. IL-17/Th17 pathway is activated in acne lesions. *PLoS One.*, 9(8), e105238. doi: 10.1371/journal.pone.0105238.
- Li, Z.J., Sohn, K.C., Choi, D.K., Shi, G., Hong, D., Lee, H.E., et al. 2013. Roles of TLR7 in activation of NF- κ B signaling of keratinocytes by imiquimod. *PLoS One.*, 8(10), e77159. doi: 10.1371/journal.pone.0077159.
- Luo, D.Q., Wu, H.H., Zhao, Y.K., Liu, J.H., Wang, F., 2016. Original Research: Different imiquimod creams resulting in differential effects for imiquimod-induced psoriatic mouse models. *Exp Biol Med (Maywood)*. 241(16), 1733-1738. doi: 10.1177/1535370216647183.
- Ma, F., Zhang, J., Zhang, J., Zhang, C., 2010. The TLR7 agonists imiquimod and gardiquimod improve DC-based immunotherapy for melanoma in mice. *Cell Mol Immunol.*, 7(5), 381-388. doi: 10.1038/cmi.2010.30.
- Moos, S., Mohebiany, A.N., Waisman, A., Kurschus, F.C., 2019. Imiquimod-Induced Psoriasis in Mice Depends on the IL-17 Signaling of Keratinocytes. *J Invest Dermatol.*, 139(5), 1110-1117. doi: 10.1016/j.jid.2019.01.006.
- Swindell, W.R., Michaels, K.A., Sutter, A.J., Diaconu, D., Fritz, Y., Xing, X., et al. 2017. Imiquimod has strain-dependent effects in mice and does not uniquely model human psoriasis. *Genome Med.*, 9(1), 24. doi: 10.1186/s13073-017-0415-3.
- Takahashi, T., Yamasaki, K., 2020. Psoriasis and Antimicrobial Peptides. *Int J Mol Sci.*, 21(18), 6791. doi: 10.3390/ijms21186791.
- Ueyama, A., Yamamoto, M., Tsujii, K., Furue, Y., Imura, C., Shichijo, M., et al. 2014. Mechanism of pathogenesis of imiquimod-induced skin inflammation in the mouse: a role for interferon-alpha in dendritic cell activation by imiquimod. *J Dermatol.*, 41(2), 135-143. doi: 10.1111/1346-8138.12367.
- Van der Kolk, T., Assil, S., Rijneveld, R., Klaassen, E.S., Feiss, G., Florencia, E., et al. 2018. Comprehensive, Multimodal Characterization of an Imiquimod-Induced Human Skin Inflammation Model for Drug Development. *Clin Transl Sci.*, 11(6), 607-615. doi: 10.1111/cts.12563.
- Vertebrate Animal Research. 2020. *Anesthesia (Guideline)*, Available from : <https://animal.research.uiowa.edu/iacuc-guidelines-anesthesia>.
- World Health Organization. 2016. *Global Report on Psoriasis*. World Health Organization. <https://apps.who.int/iris/handle/10665/204417>.

ORIGINALITY REPORT

7%

SIMILARITY INDEX

2%

INTERNET SOURCES

5%

PUBLICATIONS

5%

STUDENT PAPERS

PRIMARY SOURCES

1

Submitted to Universitas Jenderal Soedirman

Student Paper

4%

2

scitepress.org

Internet Source

2%

3

Binbin Li, Shucheng He, Rui Liu, Liangliang Huang et al. "Total glucosides of paeony attenuates animal psoriasis induced inflammatory response through inhibiting STAT1 and STAT3 phosphorylation", Journal of Ethnopharmacology, 2019

Publication

2%

Exclude quotes On

Exclude bibliography On

Exclude matches < 2%