

Turnitin AIP 1

by Mekar Anggraeni

Submission date: 04-Apr-2023 07:14AM (UTC+0700)

Submission ID: 2055094363

File name: AIP_DRTPM_2021.pdf (491.06K)

Word count: 166

Character count: 14533

Prediction of bilirubin concentration using neonatal forehead images

Cite as: AIP Conference Proceedings **2553**, 020026 (2022); <https://doi.org/10.1063/5.0103722>
Published Online: 22 November 2022

Mekar Dwi Anggraeni, Amin Fatoni and Eni Rahmawati



View Online



Export Citation

ARTICLES YOU MAY BE INTERESTED IN

1

[A green chemistry approach using Alternanthera brasiliensis extract for urea biosensor](#)
AIP Conference Proceedings **2553**, 020020 (2022); <https://doi.org/10.1063/5.0103678>

[Non-invasive neonatal jaundice determination using smartphone camera](#)

AIP Conference Proceedings **2553**, 020012 (2022); <https://doi.org/10.1063/5.0103718>

[Synthesis and photocatalytic properties of Cr-doped SrTiO₃ with Ti deficiency for enhanced photocatalytic activity](#)

AIP Conference Proceedings **2553**, 020018 (2022); <https://doi.org/10.1063/5.0104312>



APL Quantum

CALL FOR APPLICANTS

Seeking Editor-in-Chief

Prediction of Bilirubin Concentration using Neonatal Forehead Images

Mekar Dwi Anggraeni^{1, a)}, Amin Fatoni^{2, b)}, and Eni Rahmawati^{1, c)}

¹*Department of Nursing, Faculty of Health Sciences, Universitas Jenderal Soedirman, Jl Dr Soeparno 61, Purwokerto, Indonesia*

²*Department of Chemistry, Faculty of Mathematics and Natural Sciences, Universitas Jenderal Soedirman, Jl Dr Soeparno, Purwokerto, Indonesia*

^{a)} Corresponding author: mekar.anggraeni@unsoed.ac.id

^{b)} aminfatoni@unsoed.ac.id

^{c)} eni.rahmawati@unsoed.ac.id

Abstract. Neonatal jaundice is one of the most common reasons for hospital admission in the neonatal care unit, which it is associated to significant morbidity and mortality. Neonatal jaundice, indicated with hyper bilirubin in neonatal blood, occur in 60% of >35 weeks neonatal and 80% of <35 weeks neonatal. Therefore, it is important to develop the ease method to predict the hyper bilirubin in neonatal. This study was performed to develop the easy and objective method to determine the bilirubin in neonatal based on the forehead image captured using smartphone camera. Methodology of this research including the capturing of the neonatal forehead with the calibration color chart, followed by analyzing the image using ImageJ software to extract the color intensity of the digital images. The red, green and blue (RGB) colors were then analyzed to find the best correlation between the color intensity of neonatal forehead images with the blood bilirubin concentration. The bilirubin concentration was determined using standard method performed in the hospital based on spectrophotometric method. The smartphone-based methods of neonatal forehead images showed a linear correlation ($R^2=0.832$) between blue color intensity and blood bilirubin concentration of neonatal observed with a regression line of $y=-4.954x + 160.45$. This result could be used for further self-detection by the mothers of neonatal jaundice or healthcare monitoring mainly in the remote area.

INTRODUCTION

The infant mortality rate (IMR) is one indicator of a country's health status. IMR in Indonesia is the highest in Southeast Asia [1]. IMR in Indonesia is very high at 26.9 per 1000 live births [2]. One of the causes of the high IMR in Indonesia is hyperbilirubinemia in newborns [2]. The results of research conducted by Utami [3] showed that almost (48%) of newborns had hyperbilirubinemia.

Hyperbilirubinemia is a serious health problem. The effects of hyperbilirubinemia in infants are hearing loss [4], general movement disorders [5], speech delay with hearing loss [6], bilirubin encephalopathy, moro reflex disorders, opisthotonos, vomiting, and death. Long-term manifestations of hyperbilirubinemia in infants are spasticity, choreoathetosis, and sensorineural deafness [7].

The clinical manifestation of hyperbilirubinemia is discoloration of the skin and sclera. Yellow color in the skin is an indicator of an increase in bilirubin levels which is known through physical examination in infants [8]. Physical examination through visual inspection provides inaccurate data, is highly subjective, highly dependent on experience, and may give inaccurate results [9]. Laboratory tests performed to assess bilirubin levels in the blood provide accurate results, the cost of equipment is expensive, requires special expertise, and primary health facilities are not always

available. A method is needed that can be used by health workers to assess hyperbilirubinemia in infants without invasive measures, providing good results, accurate, real time, easy, and cheap.

Cellular phones (smartphones) are developing very quickly in the world. The use of smartphone camera for detection methods have been previously reported to predict the hemoglobin level [10], food safety[11], iron in water [12] and also and glucose[13]. Smartphone have the potential to be used as an early detection tool for hyperbilirubinemia in newborns using the basic principle of digital image analysis. The neonatal skin color for hyper bilirubin prediction using smartphone could be used to replace the conventional method of visual examination of the inferior palpebral conjunctiva area [8]. The development of a simple tool for early detection of hyperbilirubinemia in neonatal will increase the objectivity of the examination results. The use of cameras on cell phones for early detection of hyperbilirubinemia in newborns is interested in developing country as a program for reduce the infant mortality rate by early hyperbilirubinemia prediction in neonatal.

METHODS

Study design

Thirty-one neonatal has been ask as participant (inform consent filled by mothers) in the district hospital with the inclusion criteria of neonatal with the hyperbilirubinemia. The images have been captured before and after treatment of the neonatal, therefore a range of bilirubin concentration from normal (after treatment) and hyperbilirubinemia (before treatment) could be collected. The blood bilirubin of the neonatal have been analyzed according to the standard method and timelines in the hospital without any researcher intervention.

Neonatal forehead image capturing

Neonatal forehead images were captured using smartphone camera (Redmi, Camera 13 MP, f/2.0, PDAF) under sufficient lighting without using camera flash. A printed reflective color chart reference[14] has been place besides the neonatal (**Fig. 1**). Photograph of neonatal forehead was taken at a distance about 50-60 cm for 3 times.



Figure 1. Neonatal forehead image capturing with a reflective color chart reference.

Image analysis

Neonatal forehead images were transferred from the smartphone to a laptop (MacBook Air, Apple Inc.) without any treatment or adjusting. The forehead digital images were then analyzed using ImageJ software ver. 1.52k (National

Institute of Health, USA. <http://imagej.nih.gov/ij>). The images were extracted their color intensity of Red, Green and Blue (RGB) by simple hover the laptop mouse over the forehead of the neonatal images. Three difference location have been recorded for their RGB intensity. The standard color chart has been used to correct the images.

Data analysis

Raw data of RGB color intensity of neonatal forehead were collected. The color intensity was then adjusted according to the white, grey and yellow color of the standard color chart. The bilirubin concentration of blood neonatal reported in the medical record of the neonatal has also been collected. Neonatal forehead color intensities as the dependent variables were then analyzed using simple regression (Microsoft Excel) related to the blood bilirubin concentration as the independent variables. The analysis would result a regression line with the regression equation and coefficient of determination. The three RGB color intensity were separately analysis and the color with the highest coefficient of determination has been selected.

RESULTS AND DISCUSSION

Study participants

Neonatal participant data have been collected with birth weight of 1526 to 3900 g. The blood bilirubin concentrations were 11 to 25.9 mg/dL with average of 16.6 mg/dL. The age of neonatal mothers were 19 to 41 years with an average of 32 years. The neonatal jaundice symptoms appear from 2 days to 26 days from birth, with average of 6.9 days. The neonatal were 69% cesarean birth and the rest natural birth. The gestational ages were 31 to 41 weeks. These participants data could be important information for further neonatal jaundice profiles.

Neonatal image capturing and processing

Neonatal mothers' participants have been confirmed their approving for neonatal forehead images capturing using a smartphone. The research assistant was also first explained the description and aimed of this research. There is no compulsion to become a respondent in this study. The forehead has been chosen since forehead is one of the most stable sites of neonatal [15] and also it has a large flat surface for easy image analysis. The image capturing could be repeated to get the best lighting condition and neonatal position. The collected forehead images were then analyzed. Standard color chart was used to correct the images by adding or reducing the color intensity, when the value of color intensity of white and yellow color was significantly (more than 3 point) different with another images. The average color intensities of standard white color in the captured images were $R = 201.5$, $G = 237.5$ and $B = 239$. Whereas the average of color intensities of the yellow standard color chart was $R = 202$, $G = 200.7$ and $B = 0.8$. Various methods have been reported to correct the digital image processing such as the use of white paper [10], software based white balance [16], red label based white balance [17] and standard color chart [14]. The use of standard color chart in this research was performed to easy comparison with various color for further smartphone software development where all standard color available in the sample images.

Regression analysis

The neonatal forehead images color intensity showed a linear relationship between forehead image and blood bilirubin concentration of the participants. RGB color intensity of the neonatal forehead showed that the blue color intensity had highest relationship with the coefficient of determinant of $R^2 = 0.832$ (**Fig. 2**). The blue color intensity showed the highest relationship between color intensity and bilirubin concentration compare to red and green color intensity. The lowest relationship was the red color intensity; therefore, the yellowest skin represents the lowest blue color intensity and the highest blood bilirubin concentration. The standard color chart intensity of yellow color also showed the RGB values was about red of 200, green of 200 and blue of 0.

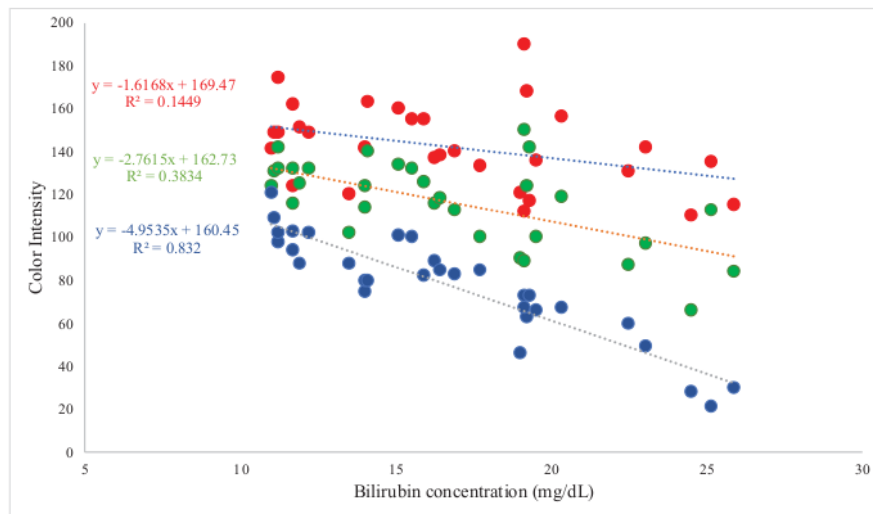


Figure 2. Relationship between neonatal forehead images color intensity and blood bilirubin obtained by hospital laboratory (n=31). Dotted line represents best fit by linear regression.

Factors effecting neonatal jaundice

Neonatal jaundice is common event occur in the first week of birth [18] and it is common causes of the neonatal hospitalization. Imbalance between bilirubin metabolism leads to increase the blood bilirubin concentration. This imbalance of metabolism due to the immature liver for rapid breakdown the red blood cells due to several factors [19]. Gestational age was one of several factors related to neonatal jaundice [19]. Gestational age <39 weeks showed increase the incidence of jaundice [20]. The participants of this research showed that the average of gestational age was 37.8 weeks, with the minimum of 31 weeks and maximum of 41 weeks. Induced labor was also reported slightly increase the neonatal jaundice incidence [21]. The result of data analysis in the participants showed the 43,5% neonatal from the induced labor.

CONCLUSION

The neonatal hyper bilirubin could be predicted using a smartphone camera, with a high correlation between blue color intensity if neonatal forehead images and blood bilirubin concentration. The use of digital image would be useful and more objective than visual observation where the instrumentation not available for neonatal hyper bilirubin detection, especially in the remote area.

ACKNOWLEDGMENT

We would like to thank the Directorate General of Higher Education (DGHE, DIKTI) and the Jenderal Soedirman University for supporting this research through “Penelitian Dasar Unggulan Perguruan Tinggi” grant no T/1422/UN23.18/PT.01.01/2021.

REFERENCES

1. World Health Organization, *World Health Statistics 2015* (World Health Organization, 2015).
2. Indonesian Ministry of Health, *Profil Kesehatan Indonesia Tahun 2019* (2019).
3. T. Utami, *J. Viva Med.* **6**, 26 (2013).
4. A.E. Raditya, Peran hiperbilirubinemia terhadap kejadian gangguan pendengaran sensori pada bayi, Master Thesis, Universitas Gadjah Mada, 2015

5. P.A. Pattinama, A.H. Putranti, and G.I. Sarosa, *Sari Pediatr.* **14**, 122 (2016).
6. S.N.L. Sari, Y.D. Memy, and A. Ghanie, *J. Kedokt. Dan Kesehatan. Publ. Ilm. Fak. Kedokt. Univ. Sriwij.* **2**, 121 (2015).
7. B.O. Olusanya, S. Teeple, and N.J. Kassebaum, *Pediatrics* **141**, (2018).
8. M.J. Maisels, *Pediatr. Rev.* **27**, 443 (2006).
9. V.A. Moyer, C. Ahn, and S. Sneed, *Arch. Pediatr. Adolesc. Med.* **154**, 391 (2000).
10. M.D. Anggraeni and A. Fatoni, in *IOP Conf. Ser. Mater. Sci. Eng.* (2017).
11. H.W. Yulia and A. Fatoni, *J. Farm. Sains Dan Komunitas* **15**, 7 (2018).
12. A. Fatoni and M.D. Zusfahair, in *J. Phys. Conf. Ser.* (2020), p. 12030.
13. A. Soni and S.K. Jha, *Anal. Chim. Acta* **996**, 54 (2017).
14. J.C.A. Fernandes, J.A.B.C. Neves, M.J.S. Freitas, and J.L. Afonso, in *2008 IEEE Int. Symp. Ind. Electron.* (IEEE, 2008), pp. 1025–1028.
15. G. Inamori, U. Kamoto, F. Nakamura, Y. Isoda, A. Uozumi, R. Matsuda, M. Shimamura, Y. Okubo, S. Ito, and H. Ota, *Sci. Adv.* **7**, eabe3793 (2021).
16. J.-H. Seo, Y.-B. Park, and Y.-J. Park, *Eur. J. Integr. Med.* **6**, 322 (2014).
17. Y. Zhao, J. Tao, and P. Tu, *Photodiagnosis Photodyn. Ther.* **10**, 96 (2013).
18. A.K. Akobeng, *Am. Fam. Physician* **71**, 947 (2005).
19. S.Y. Mojtahedi, A. Izadi, G. Seirafi, L. Khedmat, and R. Tavakolizadeh, *Open Access Maced. J. Med. Sci.* **6**, 1387 (2018).
20. S. Mitra and J. Rennie, *Br. J. Hosp. Med.* **78**, 699 (2017).
21. R. Seyedi, M. Mirghafourvand, and S. Osouli Tabrizi, *Int. J. Pediatr.* **5**, 6541 (2017).

Turnitin AIP 1

ORIGINALITY REPORT

7%

SIMILARITY INDEX

7%

INTERNET SOURCES

0%

PUBLICATIONS

0%

STUDENT PAPERS

PRIMARY SOURCES

1

www.researchgate.net

Internet Source

7%

Exclude quotes On

Exclude bibliography On

Exclude matches < 2%