

ISSN 2621-1408



# smart medical journal

Fakultas Kedokteran  
Universitas Sebelas Maret

Volume 5, No 2 2022

# Editorial Team

## Chief of Editor

- [Nanang Wiyono, dr., M.Kes](#), (ID SCOPUS : 57205482297) Fakultas Kedokteran Universitas Sebelas Maret Surakarta, Indonesia

## Editorial Board

- [Dr. Muhamad Alfakri B. MAT NOH](#), Department of Anatomy, Faculty of Medicine, Universiti Malaya
- [Nurina Tyagita, dr, M.Biomed](#), (SCOPUS ID: 57200984524) Universitas Sultan Agung Semarang
- [Sigit Setyawan, dr., M.Sc](#), (ID SCOPUS : 57210267779) Fakultas Kedokteran Universitas Sebelas Maret Surakarta, Indonesia
- [Siti Munawaroh, dr., MMedEd](#), Fakultas Kedokteran Universitas Sebelas Maret Surakarta, Indonesia
- [Ratih Dewi Yudhani, dr., M.Sc](#), (ID SCOPUS : 57204563684) Fakultas Kedokteran Universitas Sebelas Maret Surakarta, Indonesia
- [Yunia Hastami, dr., MMedEd](#), Fakultas Kedokteran Universitas Sebelas Maret, Indonesia
- [Nurhasan Agung Prabowo](#), (ID SCOPUS : 57221614740) RS UNS
- [Dr.Fitranto Arjadi, dr., MKes](#), (ID SCOPUS : 57198886122) Fakultas kedokteran, Universitas Jendral Soedirman, Purwokerto, Indonesia

## Vol 5, No 2 (2022)

## Smart Medical Journal

## Table of Contents

### Articles

#### [Pemphigus Vulgaris Management in Elderly Patient: A Case Report](#)

Prayogi Miura Susanto, Wisyanti Mian Uli Siahaan

[PDF](#)

70-77

#### [Meta-Analysis of Enteral Lactoferrin Supplementation for Reducing the Risk of Preterm Infants Sepsis](#)

Yehuda Tri Nugroho Supranoto, Dini Cynthia Dewi Tanuwijaya

[PDF](#)

78-92

#### [The Association Between Age Groups with Clinicopathologic and Molecular Subtypes of Breast Cancer Patients](#)

Tejo Jayadi, Brenda Miriane Rustam, Puji Kristi, Ngesti Chintia Dewi, Wiwiek Probowati, Hariatmoko Hariatmoko, Jonathan Willy Siagian

[PDF](#)

93-96

#### [Clinical Profile of Children Hospitalized with COVID-19 in Indonesia's District Hospital : A First Year Pandemic Wave Single Centre Study](#)

Dina Luthfiyah, Muhammad Ali Shodikin

[PDF](#)

97-105

#### [Relationship between RALE Score, Age, Gender, D-Dimer, Diabetes Mellitus and Hypertension with Mortality Rate of COVID-19 Patients in the Intensive Care Unit](#)

Ivan Ferdion, Widiastuti Widiastuti, Yusup Subagio, Hari Wujoso

[PDF](#)

106-115

#### [Preservation of Goat Kidneys Using Low Concentration Formalin for Human Anatomy Learning](#)

Sindhu Wisesa, Khusnul Muflikhah, Mustofa Mustofa, Fitranto Arjadi

[PDF](#)

116-122

#### [A 21-Year-Old Woman with Suspecting Gitelman Syndrome](#)

Berty Denny, Nurhasan Agung Prabowo, Desy Puspa Putri, Risalina Myrtha, Hendrastutik Apriningsih

[PDF](#)

123-130

# Editorial Policies

## Focus and Scope

Smart Medical Journal (SMedJour) publishes original research **articles or systematic review** in the **basic medical sciences, clinic medical sciences, medical education and public health**

Smart Medical Journal is a **peer-reviewed** and **open access journal** that focuses on promoting medical sciences generated from **basic sciences, clinical, community or public health research**, and **medical education** to integrate researches in all aspects of human health. This journal publishes **original articles, reviews**, and also interesting **case reports**. Brief communications containing short features of medicine, latest developments in diagnostic procedures, treatment, or other health issues that is important for the development of health care system are also acceptable. Letters and commentaries of our published articles are welcome.

## Section Policies

### Articles

☒ Open Submissions      ☒ Indexed      ☒ Peer Reviewed

## Peer Review Process

### PEER REVIEW PROCESS

Articles submitted to [Smart Medical Journal](#) (ISSN 2621-1408 (Print) 2621-0916 (Online)) will be evaluated through 2 stages of review, ie pre-review and substance review.

The pre-review of the article is carried out by the editorial team to review the conformity of the article with the focus and scope of the journal as well as the journal style and specific writing guidelines. Plagiarism checking is carried out by using Google Scholar and Turnitin software. Duration of review between 1-2 weeks.

Substantial single-blind reviews are performed by at least 2 reviewers. Duration of review between 3-8 weeks. If desired, the reviewer may request a re-review after the author revises his/her article.

The decision of whether the article can be published is authorized by the Editor in Chief by considering recommendations from reviewers. Articles that have been accepted and have been in-layout will be published in the In Progress issue before the regular issue is published on schedule, so they can be indexable and citable immediately.

If you would like to become a reviewer for [Smart Medical Journal](#) please contact us. You should provide some descriptive words of your reviewing interests. We will register you as a Reviewer and an Author into [Smart Medical Journal](#) within 3 working days. Your account information, i.e. username and password, will be delivered to your email.

## Publication Frequency

*Smart Medical Journal publishes three times in a year, (1) April, (2) August and (3) December*

## Open Access Policy

This journal provides immediate open access to its content on the principle that making research freely available to the public supports a greater global exchange of knowledge.

## Archiving

This journal utilizes the LOCKSS system to create a distributed archiving system among participating libraries and permits those libraries to create permanent archives of the journal for purposes of preservation and restoration. [More...](#)

# Publication Ethics

## Publication Ethics and Malpractice Statement

Smart Medical Journal ( 2621-1408 (Print) 2621-0916 (Online)) is a peer-reviewed electronic journal. This statement clarifies the ethical behavior of all parties involved in the act of publishing an article in this journal, including the author, the chief editor, the Editorial Board, the peer-reviewer and the publisher (*Fakultas Kedokteran Universitas Sebelas Maret Surakarta*). This statement is based on [COPE's Best Practice Guidelines for Journal Editors](#).

## Ethical Guideline for Journal Publication

The publication of an article in a peer-reviewed Smart Medical Journal is an essential building block in the development of a coherent and respected network of knowledge. It is a direct reflection of the quality of the work of the authors and the institutions that support them. Peer-reviewed articles support and embody the scientific method. It is therefore important to agree upon standards of expected ethical behavior for all parties involved in the act of publishing: the author, the journal editor, the peer reviewer, the publisher, and the society.

*Fakultas Kedokteran Universitas Sebelas Maret Surakarta* as the publisher of Smart Medical Journal takes its duties of guardianship over all stages of publishing extremely seriously and we recognize our ethical and other responsibilities. We are committed to ensuring that advertising, reprint or other commercial revenue has no impact or influence on editorial decisions. In addition, the *Fakultas Kedokteran Universitas Sebelas Maret Surakarta* and Editorial Board will assist in communications with other journals and/or publishers where this is useful and necessary.

## Publication decisions

The editor of the Smart Medical Journal is responsible for deciding which of the articles submitted to the journal should be published. The validation of the work in question and its importance to researchers and readers must always drive such decisions. The editors may be guided by the policies of the journal's editorial board and constrained by such legal requirements as shall then be in force regarding libel, copyright infringement and plagiarism. The editors may confer with other editors or reviewers in making this decision.

## Fair play

An editor at any time evaluates manuscripts for their intellectual content without regard to race, gender, sexual orientation, religious belief, ethnic origin, citizenship, or political philosophy of the authors.

## Confidentiality

The editor and any editorial staff must not disclose any information about a submitted manuscript to anyone other than the corresponding author, reviewers, potential reviewers, other editorial advisers, and the publisher, as appropriate.

## Disclosure and conflicts of interest

Unpublished materials disclosed in a submitted manuscript must not be used in an editor's own research without the express written consent of the author.

## Duties of Reviewers

### *Contribution to Editorial Decisions*

Peer review assists the editor in making editorial decisions and through the editorial communications with the author may also assist the author in improving the paper.

### *Promptness*

Any selected referee who feels unqualified to review the research reported in a manuscript or knows that its prompt review will be impossible should notify the editor and excuse himself from the review process.

### *Confidentiality*

Any manuscripts received for review must be treated as confidential documents. They must not be shown to or discussed with others except as authorized by the editor.

### *Standards of Objectivity*

Reviews should be conducted objectively. Personal criticism of the author is inappropriate. Referees should express their views clearly with supporting arguments.

### *Acknowledgement of Sources*

Reviewers should identify relevant published work that has not been cited by the authors. Any statement that an observation, derivation, or argument had been previously reported should be accompanied by the

relevant citation. A reviewer should also call to the editor's attention any substantial similarity or overlap between the manuscript under consideration and any other published paper of which they have personal knowledge.

#### *Disclosure and Conflict of Interest*

Privileged information or ideas obtained through peer review must be kept confidential and not used for personal advantage. Reviewers should not consider manuscripts in which they have conflicts of interest resulting from competitive, collaborative, or other relationships or connections with any of the authors, companies, or institutions connected to the papers.

### **Duties of Authors**

#### *Reporting standards*

Author's reports of original research should present an accurate account of the work performed as well as an objective discussion of its significance. Underlying data should be represented accurately in the paper. A paper should contain sufficient detail and references to permit others to replicate the work. Fraudulent or knowingly inaccurate statements constitute unethical behavior and are unacceptable.

#### *Data Access and Retention*

Authors are asked to provide the raw data in connection with a paper for editorial review, and should be prepared to provide public access to such data (consistent with the ALPSP-STM Statement on Data and Databases), if practicable, and should in any event be prepared to retain such data for a reasonable time after publication.

#### *Originality and Plagiarism*

The authors should ensure that they have written entirely original works, and if the authors have used the work and/or words of others that this has been appropriately cited or quoted.

#### *Multiple, Redundant or Concurrent Publication*

An author should not, in general, publish manuscripts describing essentially the same research in more than one journal or primary publication. Submitting the same manuscript to more than one journal concurrently constitutes unethical publishing behavior and is unacceptable.

#### *Acknowledgement of Sources*

Proper acknowledgment of the work of others must always be given. Authors should cite publications that have been influential in determining the nature of the reported work.

#### *Authorship of the Paper*

Authorship should be limited to those who have made a significant contribution to the conception, design, execution, or interpretation of the reported study. All those who have made significant contributions should be listed as co-authors. Where there are others who have participated in certain substantive aspects of the research project, they should be acknowledged or listed as contributors. The corresponding author should ensure that all appropriate co-authors and no inappropriate co-authors are included on the paper and that all co-authors have seen and approved the final version of the paper and have agreed to its submission for publication.

#### *Hazards and Human or Animal Subjects*

If the work involves chemicals, human, animals, procedures or equipment that have any unusual hazards inherent in their use, the author must clearly identify these in the manuscript.

#### *Disclosure and Conflicts of Interest*

All authors should disclose in their manuscript any financial or another substantive conflict of interest that might be construed to influence the results or interpretation of their manuscript. All sources of financial support for the project should be disclosed.

#### *Fundamental errors in published works*

When an author discovers a significant error or inaccuracy in his/her own published work, it is the author's obligation to promptly notify the journal editor or publisher and cooperate with the editor to retract or correct the paper.

## **Article Processing Charges**

Smart Medical Journal is an open access international journal. This Open Access journal does not charge any processing or publishing fees for every article published.

## **Plagiarism policy**

The manuscript that submitted into this journal will be screened for plagiarism using turnitin. Manuscript with similiarity rate more than 25% will be return immediately to the author(s).

## **Indexing**

[Google Scholar](#)

[Dimensions](#)

[Portal Garuda](#)

[Sinta](#)

# Preservation of Goat Kidneys Using Low Concentration Formalin for Human Anatomy Learning

Sindhu Wisesa<sup>1\*</sup>, Khusnul Muflikhah<sup>2</sup>, Mustofa Mustofa<sup>2</sup>, Fitranto Arjadi<sup>1</sup>

1. Department of Anatomy, Faculty of Medicine, Jenderal Soedirman University
2. Department of Physiology, Faculty of Medicine, Jenderal Soedirman University

\* Corresponding author's email: sindhu.wisesa@unsoed.ac.id

## ABSTRACT

**Background:** Exposure to formaldehyde from a preserved cadaver can cause several health problems in students, lecturers, and laboratory technicians working in medical anatomy laboratories. These conditions include respiratory tract irritation and cancer due to acute and chronic exposure, respectively. Lowering the frequency of contact with formaldehyde from preserved organs helps to ensure the safety of students, lecturers, and laboratory technicians. Therefore, this study aims to determine the effectiveness of low concentration formalin as a preservative solution for goat kidneys. The organ was selected due to its anatomical structure similarity to humans.

**Method:** Goat kidneys with 50-60 ml of volume were collected, washed, immersed in preservative solution, and stored for two months. The samples were then divided into four groups, which were preserved with different formalin concentrations, namely 30%, 20%, 10%, and 5%. The preservation parameters, namely organ structure and integrity, color, springiness, odor, and mold growth were qualitatively described, while the kidney volume was quantitatively measured.

**Results:** After the samples were preserved for two months, they were observed, and all groups showed similar characteristics. The kidneys preserved with 5% or 10% formalin showed equal volume before and after two months of preservation.

**Conclusion:** Low concentration formalin has the same effectiveness in preserving goat kidneys as the high concentration. It also has the potential to be applied in human anatomy learning.

**Keywords:** *cadaver; formaldehyde; goats; kidney*

## INTRODUCTION

A Cadaver is a preserved dead human body, which is often used for anatomy learning in the fields of medicine<sup>1</sup>. From the renaissance period until the 21<sup>st</sup> century, embalmed cadavers were used for dissection and learning, and have not been fully replaced with the interactive multimedia method until now<sup>2-5</sup>. Compared to artificial anatomical figures, they show a keen precision of anatomical structure and complexity, which portray the anatomy of living humans. Moreover, touching and palpating preserved cadavers by medical

students provide a better three-dimensional picture of the body. Students also agreed that learning with this method helps them to understand anatomy completely<sup>5-7</sup>. Previous studies revealed that preserved cadavers using typical embalming formulas, such as formalin show a different color, consistency, and organ volume compared to living humans<sup>8,9</sup>.

Formalin is a solution containing approximately 40% formaldehyde, which can easily evaporate at room temperature, hence, its exposure to the eyes and respiratory tract is difficult to avoid<sup>10,11</sup>. Acute exposure to formaldehyde irritates the eyes and respiratory

tract, which causes sore eyes, throat inflammation, or breathlessness<sup>12-15</sup>. Its odor also made students uncomfortable while learning anatomy from the preserved cadaver<sup>12,16</sup>. Several studies also showed that formaldehyde is potentially carcinogenic in chronic exposure in humans and animals, and can cause nasopharyngeal cancer, sinonasal cancer, and leukemia<sup>10,11,15</sup>.

Formalin is still used for preserving cadavers because it is inexpensive, widely available, and can excellently preserve the detailed structure, which makes the preservative suitable for dissection and anatomy learning<sup>2,17</sup>. However, its formaldehyde content is toxic, harmful to the human body, and has an unpleasant odor<sup>11,12</sup>. This makes it important to lower the exposure to formaldehyde in anatomy learning to keep students safe and create a comfortable environment.

Several preservation techniques were developed to eliminate or reduce exposure by using non-formalin-based preservative solutions or simply reducing the concentration<sup>18</sup>. Low concentration formalin as a component of mixed preservative solution showed satisfactory results with supple and moist preserved organs as well as light colorization, which makes the organs easy to distinguish<sup>19-21</sup>. It also showed a reduction of unpleasant odor and a good preservation result<sup>22</sup>. There are currently no studies on the use of pure formalin without other reagents for organ preservation and a comparison of effectiveness among different concentrations. Goat kidneys were selected for this study because they have smaller dimensions as well as similar anatomical structures to humans, namely bean shape, smooth surface, reddish brown color, covered by capsule, and surrounded with perirenal fat<sup>23-25</sup>. Therefore, this study aims to compare the effectiveness of various concentrations of formalin in preserving goat kidneys.

## METHOD

### Study Design

This experimental study was conducted using a qualitative descriptive design, where all parameters were qualitatively described by the observers. A quasi-experimental pre-test and post-test design were adopted to observe the change in kidney volume.

### Sample

Goat kidneys were used for organ preservation to substitute for human kidneys. The inner part of the organ has a detailed architecture with distinguished renal pyramids, and the alteration caused by preservation or putrefaction will be noticeable. Moreover, goat kidneys showed a similar configuration compared to that of humans and had an acceptable size for macroscopic observation<sup>24-26</sup>. Samples with a volume of 50-60 ml were collected from a slaughterhouse and processed using preservation procedure in the Anatomy Laboratory of Faculty of Medicine, Jenderal Soedirman University, within eight hours after the animals were slaughtered.

### Preservation Procedure

Goat kidneys were cleansed by striping from the outer lipid layer and capsule, followed by washing with saline solution, namely 0.9% NaCl. Their volume was then measured with a measuring cylinder in milliliter (ml) by observing the water displacement before and after they were added<sup>27,28</sup>. The kidneys were then sliced at Brodell's line to visualize their inner part, followed by immersion in formalin with concentrations of 30%, 20%, 10%, or 5% formaldehyde within closed glass containers at room temperature, and stored for two months.



## Observation

After two months of preservation, the kidneys were observed for their change of structure, integrity, color, volume, springiness, odor, mold growth, and presence of organ fragments in the preservative solution. Except for volume, these parameters were described qualitatively. The structure and integrity were defined by their shape and wholeness as well as the clear differentiation of the internal structure. The color was defined based on the coloration of the inner and outer part when it was reddish brown as in fresh kidneys or it changed to pale brown as in the preserved variant. Springiness was described by the palpation of the preserved organ compared to the fresh form. The fresh kidneys were springy and tender, while the preserved form can be hard and stiff. The odor was defined as the smell of the preserved sample, namely putrefied or formalin odor, and the strength was defined by observers as strong, mild, or no odor. Mold was described by the presence of patches on the kidney surface, which can be grey, green, or white. Change in the organ volume was defined by difference in volume before and after two months of preservation.

All parameters were observed by two observers without blinding and documented by a digital camera. The classification of the parameters is presented in Table 2.

## Ethical Clearance

This study's protocol and ethical clearance were approved by The Medical Research Ethics Commission of The Faculty of Medicine, Jenderal Soedirman University, with reference number 86/KEPK/X/2016.

## RESULTS

The goat kidney showed a similar structure to humans, but it was smaller. The outer part of the fresh organ exhibited a reddish-brown color, enveloped by a transparent capsule, and covered with perirenal

fat. After incision at the Brodell's line, the inner part displayed structures called cortex in the outer layer and medulla, including pyramids, in the inner layer, which were similar to human kidneys, as shown in Figure 1.

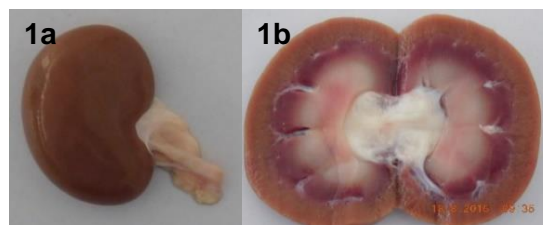


Figure 1. Structure of a fresh goat kidney (a) outer part and (b) inner part incised at the Brodell's line.

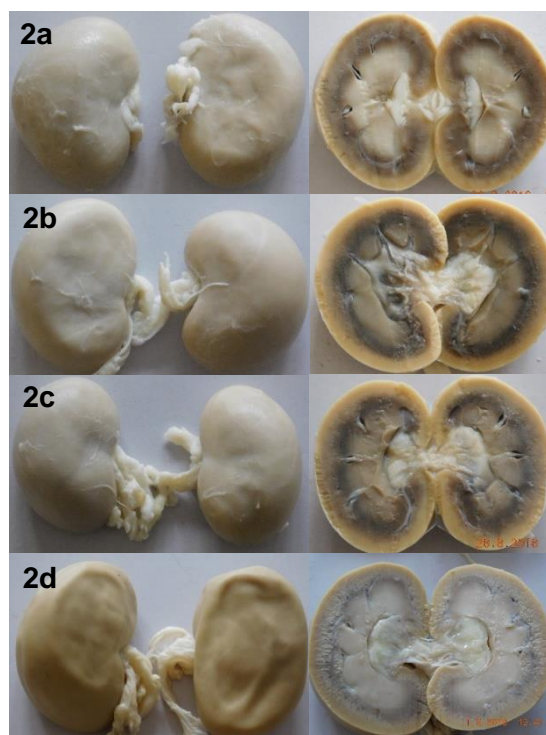


Figure 2. Structure of preserved goat kidneys. The inner and outer parts were visualized after the incision at the Brodell's line. Preservation with formalin concentrations of (a) 30%, (b) 20%, (c) 10%, and (d) 5%.

Two months of preservation using 30%, 20%, 10%, and 5% formalin showed decent and comparable results. It was observed

that they preserved the anatomical structure of the organs without putrefaction in all groups. There were also no fragments in all formalin solutions, which indicates that the integrity was well preserved, but all groups showed a pale brown color for the preserved kidneys, as shown in Figure 2.

Furthermore, the 5% and 10% formalin groups showed no reduction in kidney size after two months preservation, while the volume in the 20% and 30% groups was

reduced by 10 ml, as shown in Figure 3. The samples preserved with 5% and 10% formalin had a lesser unpleasant odor compared to the 20% or 30% group. The results showed that the springiness of the preserved kidneys in all groups was reduced when observed through the palpation technique, but the 5% and 10% exhibited better springiness compared to the 20% or 30% formalin. A summary of changes in the parameter of preserved kidneys in all groups is presented in Table 1.

Table 1. Change in characteristic and structure of goat kidney after preservation with formalin of 30%, 20%, 10%, and 5% concentration for two months.

Preservation Solution	Anatomy Structure	Integrity	Color	Volume*	Springiness	Odor	Mold
Formalin 30%	Well preserved	Well preserved	Pale brown	Reduced	Hard and stiff	Strong formalin odor, no putrefied odor	None
Formalin 20%	Well preserved	Well preserved	Pale brown	Reduced	Hard and stiff	Strong formalin odor, no putrefied odor	None
Formalin 10%	Well preserved	Well preserved	Pale brown	Equal	Springy and tender	Mild formalin odor, no putrefied odor	None
Formalin 5%	Well preserved	Well preserved	Pale brown	Equal	Springy and tender	Mild formalin odor, no putrefied odor	None

Note: Classification of parameters is described in Table 2.

\*Kidney volume before preservation and after two months preservation as shown in Figure 3.

Table 2. Classification of preserved goat kidney parameters.

Parameters	Classification	Explanation
Anatomy structure	Well preserved	Normal kidney shape (bean-shaped) and clear differentiation of structures
	Poorly preserved	Change of kidney shape or unclear differentiation of structures
Integrity	Well preserved	Intact kidney without fragmented structures
	Poorly preserved	Brittle kidney with fragmented structures
Color	Reddish brown	A similar color to that of fresh goat kidney
	Pale brown	Pale brown color appearance
Volume	Equal	No reduction of kidney volume before and after two months preservation
	Reduced	Reduction of kidney volume before and after two months preservation
Springiness	Springy and tender	Springiness and tenderness, which was similar to the fresh kidney
	Hard and stiff	Clear reduction of springiness and tenderness of the kidney was observed to be hard and stiff through palpation
Formalin Odor	No odor	No specific formalin odor perceived

Parameters	Classification	Explanation
Putrefied Odor	Mild odor	Mild and tolerable formalin odor perceived by the observers
	Strong odor	Strong and intolerable formalin odor perceived by the observers
	No odor	No specific putrefied odor perceived
Mold	Mild odor	Mild and intolerable tolerable putrefied odor judged by observers
	Strong odor	Strong putrefied odor judged by observers
	None	No patches on the kidney surface
	Presence	Presence of patches on the kidney surface

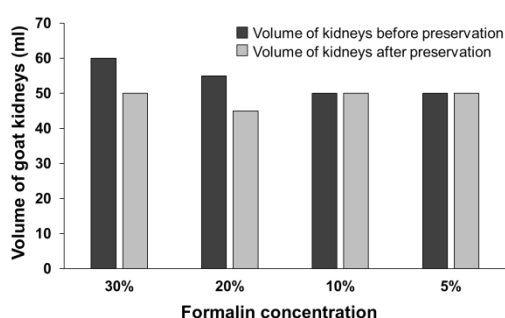


Figure 3. Changes in goat kidney volume before and after preservation with formalin concentrations of 30%, 20%, 10%, and 5% for two months.

## DISCUSSION

The use of preserved human bodies as a tool for learning anatomy or surgery has not been replaced by interactive multimedia. Apart from the three-dimensional advantage, it also provides a detailed structure of the human organs, thereby giving complete visualization for the students to study<sup>4,7,9</sup>. Anatomy laboratories often use formalin solution without dilution, which contains approximately 40% formaldehyde. However, formaldehyde is harmful to the human body, and it causes respiratory tract irritation and nasopharyngeal cancer in acute and chronic exposures, respectively<sup>10,11,15</sup>.

This study showed that low formalin concentrations of 5% and 10% showed a comparable preservation result to the 30%. There was also no alteration in kidney volume

before and after immersion in the solution for two months, and its springiness was only slightly reduced. Shrinkage after preservation with high concentration formalin was caused by the dehydration process, which involves the transfer of water from the organ to the preservative due to the difference in osmotic pressure between them<sup>9,29</sup>. However, all groups experienced decolorization to pale brown color instead of reddish-brown. This color change was caused by the oxidation of globin protein within the capillary vessel in the kidney<sup>9</sup>. A lower concentration of formalin can reduce the exposure of formaldehyde in the human body, thereby making it safer to be applied in anatomy learning compared to the higher concentration.

The limitation of this study is that it only examined the preservation of kidneys, but did not explore other organs. Various organs or a whole cadaver must be tested to define the effectiveness of the preservation solutions. The kidneys were also preserved using the immersion method, which can have a different infiltration capacity from the standard method using intravenous injection<sup>2,30</sup>. This study cannot conclude on the effectiveness of low concentration formalin for long-term preservation because the kidneys were preserved for only two months. Apart from the volume, other parameters were described qualitatively based on the observers' interpretation instead of an objective

measurement. Furthermore, this study only focused on the macrostructure of the kidneys, while the microstructure was not observed. Further studies need to be carried out to clear these issues.

## CONCLUSION

Low concentration formalin can preserve goat kidneys as effectively as the high concentration variant, hence, it can potentially be applied in human anatomy learning. This study emphasized on the benefit of low concentration preservation solutions to reduce the harmful effect of formaldehyde exposure on students, lecturers, and laboratory technicians.

## ACKNOWLEDGMENTS

The authors are grateful to Jenderal Soedirman University for funding this study with grant number DIPA-042.04.01.2.400901/2016. The authors are also grateful to the Head of Anatomy Laboratory, Faculty of Medicine, Jenderal Soedirman University, for providing the study facilities.

## Conflicts Of Interest

The authors declared that there is no competing interest.

## Author Contributions

SW designed the study construct and wrote the manuscript. SW and KM carried out the study procedures. SW, KM, MM, and FA reviewed the manuscript.

## REFERENCES

1. Ghosh SK. Human cadaveric dissection: A historical account from ancient Greece to the modern era. *Anat Cell Biol.* 2015;48(3):153–69.
2. Brenner E. Human body preservation - old and new techniques. *J Anat.* 2014;224(3):316–44.
3. Korf HW, Wicht H, Snipes RL, Timmermans JP, Paulsen F, Rune G, et al. The dissection course - necessary and indispensable for teaching anatomy to medical students. *Ann Anat.* 2008;190(1):16–22.
4. Cahill KC, Ettarh RR. Attitudes to anatomy dissection in an Irish medical school. *Clin Anat.* 2009;22(3):386–91.
5. Romi MM, Arfian N, Sari DCR. Is Cadaver Still Needed in Medical Education? *J Pendidik Kedokt Indones Indones J Med Educ.* 2019;8(3):105.
6. Winkelmann A. Anatomical dissection as a teaching method in medical school: A review of the evidence. *Med Educ.* 2007;41(1):15–22.
7. Triepels CPR, Smeets CFA, Notten KJB, Kruitwagen RFP, Futterer JJ, Vergeldt TFM, et al. Does three-dimensional anatomy improve student understanding? *Clin Anat.* 2020;33(1):25–33.
8. Older J. Anatomy: A must for teaching the next generation. *Surgeon.* 2004;2(2):79–90.
9. Beger O, Karagül Mİ, Koç T, Kayan G, Cengiz A, Yılmaz ŞN, et al. Effects of different cadaver preservation methods on muscles and tendons: a morphometric, biomechanical and histological study. *Anat Sci Int.* 2020;95(2):174–89.
10. IARC. Chemical agents and related occupations. *IARC Monogr Eval Carcinog Risks Hum.* 2012;100(Pt F):9–562.
11. NIEHS. Report on Carcinogens, Fifteenth Edition: Formaldehyde. *Natl Toxicol Program, Dep Heal Hum Serv.* 2021. <http://ntp.niehs.nih.gov/go/roc>
12. Ohmichi K, Komiyama M, Matsuno Y, Takanashi Y, Miyamoto H, Kadota T, et al. Formaldehyde exposure in a gross anatomy laboratory: Personal exposure level is higher than indoor concentration. *Environ Sci Pollut Res.* 2006;13(2):120–4.
13. Lakchayapakor K, Watchalayar P. Formaldehyde exposure of medical students and instructors and clinical symptoms during gross anatomy laboratory in Thammasat University. *J Med Assoc Thai.* 2010;93(SUPPL 7):92–8.
14. Onyije FM, Avwioro OG. Excruciating effect of formaldehyde exposure to students in gross anatomy dissection laboratory. *Int J Occup Environ Med.* 2012;3(2):92–5.
15. Nielsen GD, Larsen ST, Wolkoff P. Re-evaluation of the WHO (2010) formaldehyde indoor air quality guideline for cancer risk assessment. *Arch Toxicol.* 2017;91(1):35–61.
16. Mulu A, Tegabu D. Medical students' attitudinal changes towards cadaver dissection: a longitudinal study. *Ethiop J Health Sci.* 2012;22(1):51–8.
17. Hayashi S, Naito M, Kawata S, Qu N, Hatayama N, Hirai S, et al. History and future

- of human cadaver preservation for surgical training: from formalin to saturated salt solution method. *Anat Sci Int.* 2016;91(1):1–7.
18. Balta JY, Cronin M, Cryan JF, O'Mahony SM. Human preservation techniques in anatomy: A 21st century medical education perspective. *Clin Anat.* 2015;28(6):725–34.
  19. Kalanjati VP, Prasetiowati L, Alimsardjono H. The use of lower formalin-containing embalming solution for anatomy cadaver preparation. *Med J Indones.* 2012;21(4):203–7.
  20. Sadeesh T, Prabavathy G, Ethiraj R. Effects of high and low concentration formalin in embalming of cadavers. *Int J Curr Res Rev.* 2020;12(21):52–5.
  21. Coleman R, Kogan I. An improved low-formaldehyde embalming fluid to preserve cadavers for anatomy teaching. *J Anat.* 1998;192(3):443–6.
  22. Chhabra N. Long Term Preservation of Cadavers: Substitution of Formalin With Phenoxyethanol: Need of the Hour. *Int J Anat Res.* 2020;8(2.3):7557–63.
  23. Jabbar AI, Ali H kareem, Ibrahim RS, Lateef AN, Shalan R. Anatomical and histological invistigation of the kidney in goat (*Capra hircus*). *Karnataka J Agric Sci.* 2018;10:1–12.
  24. Maurya R, Kumar K, Kumar P. Anatomical and Physiological Similarities of Kidney in Different Experimental Animals Used for Basic Studies. *J Clin Exp Nephrol.* 2018;03(02):1–6.
  25. Rasool G, Jaiswal P, Jain A, Sharma S. Histomorphometric study of renal corpuscles of human and goat. *Natl J Clin Anat.* 2021;10(4):205–8.
  26. Vishwakarma SK, Bhavani PG, Bardia A, Abkari A, Murthy GSN, Venkateshwarulu J, et al. Preparation of natural three-dimensional goat kidney scaffold for the development of bioartificial organ. *Indian J Nephrol.* 2014;24(6):372–5.
  27. Jain LK, Babel H. an Innovative Method To Prepare Formalin Free Models By Paraffin Impregnation of Human Organs- Heart, Brain, Spleen and Liver. *Int J Anat Res.* 2017;5(2.3):3988–92.
  28. Araújo LM, Serigiolle LC, Gomes HM, Rodrigues DA, Lopes CM, Leme PL. Abdominal Cavity and the Hernial Sac in Incisional. *ABCD Arq Bras Cir Dig.* 2014;C(3):177–81.
  29. Fraser KW. Effect of storage in formalin on organ weights of rabbits. *New Zeal J Zool.* 1985;12(2):169–74.
  30. Eisma R, Wilkinson T. From “Silent Teachers” to Models. *PLoS Biol.* 2014;12(10):1–5.