



Subscribe Print Journal

Recommend this journal
TO YOUR
LIBRARY

Journal's Code

ISSN Number: 2456-2912

ICV 2016: 60.37

Impact Factor: RJIF 5.69

Issue Bar

Past Issue

Coming Issue

Side Bar

Home

About Us

Archives

Editorial Board

Indexing and Abstracting

Instructions

Contact Us

Peer Review and Publication Policy

Publication Ethics


Copyright Form

Download Copyright Form

Identifier

Welcome To

International Journal of Veterinary Sciences and Animal Husbandry



International Journal of Veterinary Sciences and Animal Husbandry is a Peer Reviewed Open Access Quarterly Journal. Prime Focus of the Journal to publish articles related to the current trends of Veterinary Sciences and Animal Husbandry.

Editor-in-Chief: Dr. Islam Uddin Sheikh

ISSN: 2456-2912

Impact Factor (RJIF): 5.69

NAAS (2023): 4.98

Media: Print and Online

DOI: <https://dx.doi.org/10.22271/veterinary>

Type: Peer Reviewed / Refereed Journal

Publication Frequency: Quarterly

International Journal of Veterinary Sciences and Animal Husbandry is an official publication of the [Society of Agricultural Research and Social Development](#) (Registration no. S/3194/SDM/NW/2018).

International Journal of Veterinary Sciences and Animal Husbandry considers review and research articles related to: **Animal Anatomy, Physiology, Biochemistry, Pharmacology, Microbiology, Pathology, Parasitology, Infectious diseases, clinical sciences, Alternative veterinary medicines and biomedical fields, Livestock production and technologies, All aspects of veterinary technology, Animal Breeding and experimental animals.**

Your views and comments will be highly acclaimed. Author can send their articles to vet.manuscript@gmail.com. All manuscripts are subjected to RAPID peer review process and those of high quality (which are not previously published and are not under consideration for publication by another journal) would be published without any delay in subsequent issues. Online submission of the manuscript is strongly recommended. A manuscript number will be mailed to the corresponding author within one week or earlier.

On the behalf of International Journal of Veterinary Sciences and Animal Husbandry, I would like to extend my regard to the all fellow researchers and scholars and wish prosperity in their field.

(Editor-in-Chief)





Subscribe Print Journal

Recommend this journal
TO YOUR
LIBRARY

Journal's Code

ISSN Number: 2456-2912

ICV 2016: 60.37

Impact Factor: RJIF 5.69

Issue Bar

Past Issue

Coming Issue

Side Bar

Home

About Us

Archives

Editorial Board

Indexing and Abstracting

Instructions

Contact Us


Peer Review and Publication Policy

Publication Ethics

Copyright Form

Download Copyright Form

Identifier

member

CROSSREF.ORG
THE CITATION LINKING BACKBONE

About Us

International Journal of Veterinary Sciences and Animal Husbandry is a Peer Reviewed International Journal. Prime Focus of the Journal to publish articles related to the current trends of research in Veterinary Sciences and Animal Husbandry.

International Journal of Veterinary Sciences and Animal Husbandry considers review and research articles related to: Animal Anatomy, Physiology, Biochemistry, Pharmacology, Microbiology, Pathology, Parasitology, Infectious diseases, clinical sciences, Alternative veterinary medicines and biomedical fields, Livestock production and technologies, All aspects of veterinary technology, Animal Breeding and experimental animals.

The journal will be abstracted and indexed in important databases, such as NISCAIR, Index Copernicus International, Chemical Abstracts, IAS (Govt. of India).



Subscribe Print Journal

Recommend this journal
TO YOUR
LIBRARY

Journal's Code

ISSN Number: 2456-2912

ICV 2016: 60.37

Impact Factor: RJIF 5.69

Issue Bar

Past Issue

Coming Issue

Side Bar

Home

About Us

Archives

Editorial Board

Indexing and Abstracting

Instructions

Contact Us

Peer Review and Publication Policy

Publication Ethics

Copyright Form











Download Copyright Form

Identifier




Editorial Board












Instructions to Reviewer [Click Here](#)

EDITOR-IN-CHIEF	
	<p>Dr. Islam Uddin Sheikh (MV.Sc., Ph.D) Professor / Chief Scientist Division of Livestock Production and Management Faculty of Veterinary Sciences and Animal Husbandry, SKUAST-Kashmir, Srinagar, Jammu and Kashmir, India Email: editor@veterinarypaper.com Phone: 01145574068</p>
ASSOCIATE EDITOR	
	<p>Dr. Mahendra Pal (BVSc & AH, MVPH, Ph.D., D.Sc.) Ex- Professor of Veterinary Public Health (UNDP) College of Veterinary Medicine, Addis Ababa University, Ethiopia Email: palmahendra2@gmail.com Phone: 9426085328</p>
	<p>Dr. M. Anna Anandh (M.V.Sc., Ph.D. (Livestock Products Technology)) Associate Professor and Head Department of Livestock Products Technology, Tamil Nadu Veterinary and Animal Sciences University (TANUVAS), Veterinary College and Research Institute, Tirunelveli, Tamil Nadu, India Email: drannaanandh@gmail.com Phone: 9443095518</p>
	<p>Dr. Sachchidananda Das Chowdhury (Ph.D) Professor Department of Poultry Science Bangladesh Agricultural University Mymensingh Bangladesh Email: drsdchow@gmail.com Phone: +8801712541494</p>
	<p>Dr. Gamal Allouch (Ph.D) Professor Department Anatomy,veterinary Medicine College, Hama University, Syria Email: gentle187@hotmail.com Phone: +966163800050</p>
	<p>Dr. Mohamed Abd El-Fatah Mahmoud Abdalla (Ph.D) Professor Department of parasites and animal diseases National Research Centre Egypt Email: m_elfatatri@yahoo.com Phone: 00201149484153</p>
	<p>Dr. Ashok Kumar Devarasetti (M.V.Sc, Ph.D) Head of the Department Department of Veterinary Biochemistry, College of Veterinary Science, Rajendranagar, Hyderabad, Telangana, India Email: ashok9901@gmail.com Phone: 9866184192</p>
	<p>Dr. M. Saleem Akhtar (Ph.D) Associate Professor Department of Clinical Science, Faculty of Veterinary Sciences, Bahauddin Zakariya University Multan Pakistan Email: drsaleemakhtar@bzu.edu.pk Phone: +923147890797</p>

	Dr. Diaa El-Sayed Eraky Abou-Kassem (Ph.D) Head of Animal and Poultry Production Department Animal and Poultry Production Department, College of Technology and Development, Zagazig University, EGYPT Email: drdiaaaboukassem_19@yahoo.com Phone: 00201025264732
	Dr. Rajkumar Berwal (M.V.Sc., Ph.D. (Livestock Products Technology)) Principal Investigator Principal Investigator, Centre for Organic Animal Products Technology, Department of Livestock Products Technology, College of Veterinary and Animal Science, Rajasthan University of Veterinary and Animal sciences (RAJUVAS) Bikaner-334001, Rajasthan, India Email: drberwalraj@gmail.com Phone: 9414482918
	Dr. Sameh M. Farouk (PhD) Associate professor Dept. of Cytology and Histology, Faculty of Veterinary Medicine, Suez Canal University, Egypt Email: dr_smf_hist@vet.suez.edu.eg Phone: 00201098395384
	Dr. Selim S. Salama (Ph. D) Chief Researcher 5 El-Farok Omar st., Faisal king, Haram, El-Giza, Egypt Email: selimsalama2000@yahoo.com Phone: +200101800205
	Dr. Mangesh Nakade (DVM, MS Ph.D) Scientist D-214,SZIE, Godollo, University, Peter Karoly utca1, Pin code 2100, Pest, Hungary, Maharashtra, India Email: drmangesh23@gmail.com Phone: 9423900848
	Dr. Lonel Bondoc (DVM, MSc, VPD, PhD) Associates Professor Faculty of Veterinary Medicine Iasi Public Health Department Head of: Control of Products and Food of Animal Origin; Food Safety; Control and Quality Assurance of Food; Legislation and Inspection of Agri-Food Products, Romania Email: bondoc_mv@yahoo.com Phone: 0040232407311
	Dr. Alvin T. Reyes (Ph. D) Associate Professor Araullo University, Cabanatuan City, Nueva Ecija, Philippines Email: alvinreyes1845@gmail.com Phone: 9171628000
	Dr. Stan Florin (Ph.D) Associate professor University education, Fundamental and preclinical sciences, Faculty of Veterinary Medicine, University of Agricultural Sciences and Veterinary Medicine, Cluj-Napoca, Romania. Email: flodvm@yahoo.com Phone: +40744244056
	Dr. Ramesh D (Ph.D.) Assistant Professor Department of Veterinary Biochemistry, Veterinary College Hassan, Karnataka Veterinary, Animal and Fisheries University, Karnataka, India
	Dr. Kamal Hashan Bulbul (Ph.D.) Associate Professor-cum-Senior Scientist Division of Veterinary Parasitology, Faculty of Veterinary Sciences and Animal Husbandry, SKUAST-Kashmir, Shuhama, Srinagar, Jammu & Kashmir, India

ASSISTANT EDITOR

	Dr. Manoj Kumar (B.V.Sc. & A.H., M.V.Sc. (Veterinary Virology)) Veterinary Officer, Central Animal House Indira Gandhi Institute of Medical Sciences, Sheikhpura, Patna, Bihar, India Email: manojvet332@gmail.com Phone: 9199681622
	Dr. Pankaj Kumar (Ph.D. (Veterinary Medicine)) Scientist (SS) DLFM, ICAR Research Complex for Eastern Region, Patna, Bihar, India Email: pankajvet@gmail.com Phone: 9473353323
	Dr. Srinivas Sathapathy Assistant Professor Veterinary Anatomy & Histology College of Veterinary Science & Animal Husbandry, Orissa University of Agriculture & Technology, Bhubaneswar, Odisha, India

	<p>Email: srinivas.sathapathy@gmail.com Phone: 09439526198</p>
	<p>Dr. Suman Kumari Joshi (Ph.D.) Scientist Krishi Vigyan Kendra, Jharsuguda, Orissa University of Agriculture & Technology Bhubaneswar Odisha, India Email: suman42.joshi@gmail.com Phone: 9439024401</p>
	<p>Dr. Shuvranshu Shekhar Biswal (Ph.D.) Assistant Professor Animal Reproduction Gynaecology and Obstetrics, College of Veterinary Sci. & Animal Husbandry, Orissa University of Agriculture & Technology, Bhubaneswar, Odisha, India Email: shuvranshu06@gmail.com Phone: 9438365519</p>
	<p>Dr. Hyacinth Anthony Ibekwe (Ph.D.) Senior Lecturer Animal Science & Agriculture and Forestry, Cross River University of Technology (CRUTECH), Calabar, Cross River State, Nigeria Email: hibekwe2010@gmail.com Phone: 08125646503</p>
	<p>Dr. Ghulam Abbas Hashmi (PhD) Assistant Professor Department of Animal Production, Riphah College of Veterinary Sciences (RCVetS), Lahore, Pakistan. Email: ghulamabbas_hashmi@yahoo.com Phone: 03060667577</p>
	<p>Dr. Drazen Duricic (PhD) Assistant Professor Obstetrics and Reproduction clinic, Faculty of Veterinary Medicine University of Zagreb, Croatia Email: djuricic@vet.hr Phone: +385911812456</p>
	<p>Dr. Syed Ishtiaq Anjum (Ph.D) Assistant Professor Department of Zoology, Kohat University of Science and Technology Kohat, Khyber Pakhtunkhwa Pakistan Email: ishtiaq11@gmail.com Phone: +923348835354</p>
	<p>Dr. Fahd Mohammed Abd Al Wahab Abd Al Galil (Ph.D) Assistant Professor Department of Biology, Faculty of Sciences, University of Bisha, Bisha 61922. P. O. Box: 551. Saudi Arabia Email: fahd.bamu78@gmail.com Phone: +966501192926</p>
	<p>Dr. Yasser M. Albadrany (Ph.D.) Lecturer College of Veterinary Medicine/University of Mosul/Iraq. Email: yasseralbadrany@yahoo.com Phone: +9647702076231</p>
	<p>Dr. Shuaib Gidado Adamu (Ph.D) Senior lecturer Department of Veterinary Public Health and Preventive Medicine, Faculty of Veterinary Medicine, University of Maiduguri, P. M. B. 1069, Maiduguri. Borno State, Nigeria Email: gidado97@gmail.com Phone: +2348035383010</p>
	<p>Dr. Emmanuel Ahaotu (Ph. D) FORMAL HEAD of DEPARTMENT Department of Animal Production and Health Technology, Imo State Polytechnic Umuagwo - Ohaji, Nigeria Email: emmaocy@yahoo.com Phone: +2348038520777</p>
	<p>Dr. Hafsa Alyamani (Ph.D) Researcher Animal Sciences, specializing in Education and Improvement (Genetics) and animal production sciences from the ukurova University in the State of Adana, Turkey Email: drhafsaalyamani@gmail.com Phone: 07058988801</p>

[Apply for Editorial Board Member Click Here](#)



Subscribe Print Journal

Recommend this journal
TO YOUR
LIBRARY

Journal's Code

ISSN Number: 2456-2912

ICV 2016: 60.37

Impact Factor: RJIF 5.69

Issue Bar

Past Issue

Coming Issue

Side Bar

Home

About Us

Archives

Editorial Board

Indexing and Abstracting

Instructions

Contact Us

Peer Review and Publication Policy

Publication Ethics

Copyright Form

Download Copyright Form

Identifier

member

CROSSREF.ORG
THE CITATION LINKING BACKBONE

Indexing and Abstracting

International Journal of Veterinary Sciences and Animal Husbandry is indexed in following database.



Subscribe Print Journal

Recommend this journal
TO YOUR
LIBRARY

Journal's Code

ISSN Number: 2456-2912

ICV 2016: 60.37

Impact Factor: RJIF 5.69

Issue Bar

Past Issue

Coming Issue

Side Bar

Home

About Us

Archives

Editorial Board

Indexing and Abstracting

Instructions

Contact Us

Peer Review and Publication Policy

Publication Ethics

Copyright Form

Download Copyright Form

Identifier

Vol. 6, Issue 3, Part A (2021)

S. No.	Title and Authors Name	Country
1	Ingluviotomy in a cumulet pigeon following crop impaction: Case report D Laku, AA Mutah, A Mohammed, SH Mshelia and AA Mohammed [ABSTRACT] [DOWNLOAD] PAGES: 01-03 525 VIEWS 48 DOWNLOADS	Nigeria
2	Profile of digestive organ and carcass yield of broiler chickens reared with free-antibiotics feed-in different elevation area in Banyumas regency, Indonesia Elly Tugiyanti and Emmy Susanti DOI: https://doi.org/10.22271/veterinary.2021.v6.i3a.350 [ABSTRACT] [DOWNLOAD] PAGES: 04-08 469 VIEWS 36 DOWNLOADS	Indonesia
3	Chemotherapy and surgical treatment of penile and vaginal transmissible venereal tumor in mongrel dogs: Case report Kachalla Alhaji Modu, Larema Mohammed Modibbo, Mohammed Babagana, Aliyu Garba, Bukar Tijjani, Adamu Hassan Jarmai, Abdullahi Abubakar Gaya and Shehu Ahmad [ABSTRACT] [DOWNLOAD] PAGES: 09-11 429 VIEWS 31 DOWNLOADS	Nigeria
4	Breeder's knowledge on ticks and tick-borne diseases and management strategies in Menoua division (Western region of Cameroon) Michel Lontsi-Demano, Maureen Laroche, Yannick Cabrel Ngnindji-Youdje, Jean-Eudes Djikolbairangar, Abdoulmoumini Mamoudou and Timoléon Tchuinkam DOI: https://doi.org/10.22271/veterinary.2021.v6.i3a.354 [ABSTRACT] [DOWNLOAD] PAGES: 12-21 534 VIEWS 35 DOWNLOADS	Cameroon
5	Treatment of chronic gastritis in an adult labrador working dog: A case study Kamble KD [ABSTRACT] [DOWNLOAD] PAGES: 22-24 338 VIEWS 19 DOWNLOADS	India
6	Treatment of transmissible venereal tumor without metastasis in mixed local Balinese dog by surgery and vincristine sulfate: A case report Dzikri Nurma'rifah Takariyanti, I Wayan Gorda and Palagan Senopati Sewoyo DOI: https://doi.org/10.22271/veterinary.2021.v6.i3a.356 [ABSTRACT] [DOWNLOAD] PAGES: 25-29 508 VIEWS 31 DOWNLOADS	Indonesia
7	Art and science: The importance of scientific illustration in veterinary medicine Andreia Garcês DOI: https://doi.org/10.22271/veterinary.2021.v6.i3a.357 [ABSTRACT] [DOWNLOAD] PAGES: 30-33 482 VIEWS 22 DOWNLOADS	Portugal
8	Effect of supplementation of multi-enzyme in low energy diet on the carcass traits and hematobiochemical parameters of broiler birds	India

	<div>Amrapali Kothare, Suneet Wankhede, Vitthal Munde, Yogeshwari Sirsat and Rahul Mogale</div> <div>[ABSTRACT] [DOWNLOAD]</div> <div>PAGES: 34-39 311 VIEWS 21 DOWNLOADS</div>	
9	<div>Bovine babesiosis: A general review</div> <div>Deepak Chandran</div> <div>[ABSTRACT] [DOWNLOAD]</div> <div>PAGES: 40-44 309 VIEWS 18 DOWNLOADS</div>	India
10	<div>Assessment of challenges associated with artificial insemination service delivery in dairy cattle in Rwanda</div> <div>Patrick Rugwiro, Evariste Manirahaba, Aphrodis Tuyishimire, Jean Claude Abijuru, Benjamin Nizeyimana, Dismas Habumugisha, Diane Uwumukiza and Pascal Nyabinwa</div> <div>[ABSTRACT] [DOWNLOAD]</div> <div>PAGES: 45-57 341 VIEWS 32 DOWNLOADS</div>	Rwanda
11	<div>Effect of restricted replacement of soybean meal with different levels of defatted apricot kernel meal on growth performance, carcass traits and blood constituents of broiler chickens</div> <div>Mahmoud Ahmed Abo Mhara</div> <div>[ABSTRACT] [DOWNLOAD]</div> <div>PAGES: 58-65 112 VIEWS 9 DOWNLOADS</div>	Libya



International Journal of Veterinary Sciences and Animal Husbandry



ISSN: 2456-2912

VET 2021; 6(3): 04-08

© 2021 VET

www.veterinarypaper.com

Received: 04-03-2021

Accepted: 06-04-2021

Elly Tugiyanti

Poultry Production Lab, Faculty
of Animal Science, Jenderal
Soedirman University,
Purwokerto, Indonesia

Emmy Susanti

Animal Feed Ingredients Lab.,
Faculty of Animal Science,
Jenderal Soedirman University,
Purwokerto, Indonesia

Profile of digestive organ and carcass yield of broiler chickens reared with free-antibiotics feed-in different elevation area in Banyumas regency, Indonesia

Elly Tugiyanti and Emmy Susanti

DOI: <https://doi.org/10.22271/veterinary.2021.v6.i3a.350>

Abstract

The research objective was to determine the digestive tract profile and carcass production of broiler chickens fed on antibiotic-free feed in areas with different elevation area. The study a survey designed according to the General Linear Model with purposive random sampling to choose farmer with 5.000-10.000 chickens Cobb strain, used opened house and free-antibiotic feed. The data was analyzed used univariate one-way analysis of variance. The result showed that the different elevation area have not significantly affected ($p>0.05$) the crop, proventriculus, duodenum weight and lenght, inter villi space, carcass weight, carcass percentage of broiler chickens fed by antibiotic-free feed. However, it has significantly affected ($P<0.05$) the weight of the final body, liver, small intestine, and it is positively considerably affected ($P<0.01$) on gizzard weight and duodenum villi height. Antibiotic-free broiler chickens have kept in an opened house with different elevation area, hold on normally digestive organs and carcass production.

Keywords: antibiotic, duodenum, meat quality, villi, carcass production

Introduction

Since January 1, 2018, Indonesia's government, through the Ministry Regulation of Ministry of Agriculture No. 14/2017, has prohibited using antibiotics as a growth promotor (Antibiotic Growth Promotor/AGP) in livestock feed. Many farmers complained that the performance and immunity of the broilers were declining. Broiler chickens genetically perform fast growth and produce quality meat (Anggitasari *et al.*, 2016) ^[5]. However, broiler chickens also have some drawbacks, such as low immunity against disease and prone to stress (Jannah *et al.*, 2017) ^[10]. Body immune would decline faster when accompanied by stress (Adedokun *et al.*, 2019) ^[1], and a distressed chicken would impact the meat quality (Shao *et al.*, 2019) ^[27]. Before the prohibition of antibiotics, almost all broiler breeders in Indonesia gave Antibiotics Growth Promoters (AGP) to the broilers through the feed.

The antibiotics activities reduce the microorganism population in the gastrointestinal tract, prevent disease, increase nutrient absorption, inhibit nutrient damage due to microorganisms, improve body growth, and improve feed efficiency (Kim *et al.*, 2017) ^[13]. Antibiotics are directly reacting with the body's chicken immune system because antibiotics would fight the infectious agents that attack the chicken (Al-Khalaifah *et al.*, 2018) ^[4]. A subtherapeutic dose of antibiotics could; however, given in the long run and ceased at the wrong time would produce antibiotics residual in the chicken carcass, meat, or visceral organs (Marlina *et al.*, 2015; Masrianto *et al.*, 2019) ^[16, 17] and bacterial resistance against antibiotics (Johnson *et al.*, 2018) ^[11]. Antibiotics also have a side effect of reinforcing bone marrow activity that causes a disorder in red blood cell formation (Pilecky *et al.*, 2019) ^[21].

Indonesia has a diverse range of temperature and humidity; the daylight temperature may exceed 34 °C, and evening humidity could reach 93%. The climate (temperature, humidity, precipitation, and interactions) significantly affect broiler chickens' performance (Nayak *et al.*, 2015) ^[20]. The research located in the south of Central Java, Banyumas Regency, is the broiler chickens centre.

Corresponding Author:

Elly Tugiyanti

Poultry Production Lab, Faculty
of Animal Science, Jenderal
Soedirman University,
Purwokerto, Indonesia

production of broiler chickens fed on antibiotic-free feed in areas with different elevation area. Our study objective was to determine the intestine organ profile, carcass

Materials and Methods

Ethical approval

The study was approved by the Indonesian Veterinary Association of Central Java II Branch, with certificate No. 02 / PDHI JT II / I / 2019 (January 7, 2019).

Study Area

This study was conducted at Banyumas Regency which have different elevation area and climatic condition (temperature, humidity, and precipitation) i.e. E1 ((Lower Elevation): 6 m above sea level (19.5-35.3° C, 90%, 425 mm³/year), E2 (Medium Elevation): 55m above sea level (20-29° C, 85%, and 3.130 mm³/year), and E3 (High Elevation): 200-1500m above sea level (22 – 29 °C, 95%, and 3.585 mm³/year).

Data Collection

The study included a survey designed according to the General Linear Model (GLM) with purposive random sampling to select farmers with 5.000-10.000 chickens of Cobb strain, used opened the house and free-antibiotic feed. An accidental sampling technique has been used to determine the number of breeders in each area. Total broiler chickens aged 35-37 days old for observation was 27 heads per each area.

The observed variables were a) the profile of digestive organs including crop weight, liver weight, and intestinal weight, b) duodenum profile including duodenum weight and length and duodenal intervillous space, c) carcass production including slaughter weight, carcass weight, and carcass percentage.

Analytical Procedure

Twenty-seven broiler chickens aged 35-37 days were randomly selected from the respondents' in each area and

rested in a litter cage for 4-6 hours before slaughter using the Kosher method. Data of crop, proventriculus, and gizzard were obtained by removing the content in these organs, then cleaning and draining the organs before they were. The liver weight data was measured by separating the liver from the bile pocket before weighing the liver. The weight of the intestinal was measured by cutting the intestines from the duodenum to ileum. Duodenum weight was measured by weighing the duodenum, while estimated duodenum length was by measuring the front end through the duodenum rear end. The height and duodenal intervillous space were measured by soaking intestine samples one by one into 70% alcohol for about 10 minutes. Then, the samples were put into xylitol and finally dipped into paraffin. The sample was thinly sliced using a microtome followed by a hematoxylin-eosin stain. A histology preparation was ready in a glass object for observation and measurement using a computer-aided microscope. The villi height, the item was determined first using an Olympus BX 51 microscope equipped with an Olympus DP 12 projector with 4-time magnification. The histology image appeared on the JVC TMH 1750C monitor screen. Then, all preparations image has captured a minimum of three times per slide of each parameter.

The slaughter weight data were the broilers' weight after being harvested and feed-fasted for 4 hours (drinking water was provided). The data was analyzed used univariate one-way analysis of variance.

Results and Discussion

Profile of Digestive Organ

The digestive tract of chickens conveys food to the stomach, and this system comprises crop (elongation of the oesophagus located in the lower neck area), glandular stomach (proventriculus), muscular stomach (gizzard), and intestines. Profile the digestive organs of broiler chickens in three different elevation areas, as presented in Table 1.

Table 1: Profile the digestive organs of broiler chickens in three different areas

Area	Crop weight (g) ^{ns}	Proventriculus weight (gm) ^{ns}	Gizzard weight (g) ^{hs}	Liver weight (g) ^s	Small intestines weight (g)s
E1	5.96±0.41 ^a	4.94±0.02 ^a	25.61±2.88 ^a	34.40± 4.93 ^a	26.22±1.10 ^a
E2	5.89±0.45 ^a	5.20 ± 0.17 ^a	29.23± 4.82 ^b	36.81±2.86 ^a	30.67±2.61 ^b
E3	6.88±0.02 ^a	5.42±0.04 ^a	35.47±2.97 ^c	46.64±5.46 ^b	31.60±3.58 ^b

^{ns} The same superscripts within the column show no difference ($P>0.05$)

^s Different superscripts within column show a significant difference ($P<0.05$)

^{hs} Different superscripts within column show a highly significant difference ($P<0.01$)

Analysis of variance result showed that the crops and proventriculus of broiler chickens that were kept under different elevation area showed no significant difference ($P>0.05$). It because the crop is the digestive organ to contain the digest temporarily. The proventriculus is the oesophagus hind part dilation, where secreted pepsinogen and HCl enzymes. Lierman *et al.* (2019) [15], stated that the contributing factors to the size of proventriculus are the size and form of feed particles. Interestingly, the temperature in E1 is higher than that in E2 and E3, but the chicken's crop in E1 does not expand despite the increased intake of water. Tamzil (2014) [28], stated that the chicken crop could enlarge due to excessive water intake. Chickens consume more water when the house temperature is higher. This study observed that the water intake of broiler chickens in E1 was the highest (4,622.53±23.40 ml) than E2 (4,340±47.88ml) or E3 (4,220±34.50 ml). This study did not observe a pendulous crop as reflected from the treatment broilers; therefore, the

chickens could tolerate the amount of water intake.

The variance analysis showed that elevation area significantly affected gizzard weight ($P<0.01$). The gizzard weight of broiler chickens in E3 was higher because the temperature, humidity, and precipitation in E3 were more appropriate than those in E1 and E2. Therefore, broiler chickens in E3 consumed the most feed of the three areas, i.e. 2.68±0.32 g/head (E3) vs 2.47±1.08g/head (E1) and 2.49±1.05g/head (E2). According to Yosi *et al.* (2017) [31], broilers need an appropriate ambient temperature in a livable condition known as the thermoneutral zone. Aluwong *et al.* (2017) [3]. Stated that 'broiler chickens' thermoneutral area is 18°C to 24°C. However, Candido *et al.* (2016) [34] argued that the convenient temperature and humidity for broiler chickens varied on the first week (33.0±0.5°C and 64.8±5.3%), second week (30.0±0.3°C and 60.3±5.7%), and the third week (27.0±0.3°C and 59.6±4.8%). Temperature and humidity that are approaching the thermoneutral zone resemble the climate in

E3. High feed intake would make the gizzard work harder to grind the feed into smaller particles; consequently, the gizzard muscle gets enlargement. The temperature in E1, especially during daylight, is very high, and low precipitation; because of nearby the sea. According to Mutibvu *et al.* (2017) [19], broiler chickens consumed more waters to maintain body temperature. High water consumption would cause low feed intake and relieve gizzard work.

The liver weights of broiler chickens (Table 1) across regencies in this study were within the normal range, which was in line with Kokoszyński *et al.* (2017) [14] reporting 42.5-49.9 g. The analysis of variance result showed that different elevation area significantly affected ($P<0.05$) liver weight because the liver performance is related to the amount of feed consumed; the more feed consumed, the harder the liver works, hence affecting the liver weight (Zaefarian *et al.*, 2019) [32]. This organ can quickly adapt to a change in feed and the environment. The contributing factors to liver weight include the type and amount of feed consumed (Kokoszyński

et al., 2017) [14].

The small intestine is a vital organ responsible for the digestion and absorption of nutrients from the diet. Analysis of variance showed that broiler farming locations with different elevation area significantly affected ($P<0.05$) the small intestines weight. It was because the broiler chickens kept in different elevation area exhibited diverse growth and body weight. This finding was supported by Kokoszyński *et al.* (2017) [14] and Purwinarto *et al.* (2020) [23] that for broiler chickens to have a fast and efficient growth as well as optimum final body weight, and it takes optimum intestinal performance (duodenum, jejunum, and ileum) as well as nerve system and circulation. This study found that the highest body weight obtained from broiler chickens kept in E3 (1.70 ± 0.71 kg), followed by that in E2 and E1, i.e., 1.75 ± 0.27 kg and 1.68 ± 0.77 kg, respectively.

Duodenum Profile

Table 2: Duodenum profile of broiler chickens in three different areas

Area	Duodenum length (cm) ^{ns}	Duodenum weight (gm) ^{ns}	Duodenum villi height (μm) ^{hs}	Inter villous space (μm) ^{ns}
E1	34.22± 3.62 ^a	6.39± 0.20 ^a	1185.57± 37.22 ^a	2.55± 0.03
E2	33.99± 2.54 ^a	6.52± 0.63 ^a	1498.54± 26.36 ^b	3.29± 0.14
E3	34.87± 3.91 ^a	6.84± 0.24 ^a	1609.11± 17.34 ^c	4.27± 0.86

^{ns} the same superscripts within column show no difference ($P>0.05$)

^s different superscripts within the column show a significant difference ($P<0.05$).

Duodenum is the longest part of the small intestines, and it functions in the digestion process and nutrient feed absorption. Feed and nutrient digestibility affected by duodenum size, villi heights, and duodenal intervillous space. Duodenum profile of broiler chickens in three different areas, as presented in Table 2. Sari *et al.* (2016) [25] and Satimah *et al.* (2019) [26] reported that the duodenum weight of broiler chickens was 4.648 g (0.7 % of body weight 664.00g) and the length was 31.00-35.00 cm. Analysis of variance result demonstrated that farming location at different elevation area did not significantly affect ($P>0.05$) duodenum weight and length of broiler chickens because the nutrient content in feed offered from the starter to harvest period was equal. According to Satimah *et al.* (2019) [26] and Wang *et al.* (2016) [30], the duodenum's weight and length were near related to the length and duodenal intervillous space, digestion process, and nutrient absorption.

Villi is the mucus membrane's projection into the small intestine lumen that extends the surface area to absorb nutrition. There are longer and more villi in the duodenum than in ileum (Prakatur *et al.*, 2019) [22]. Qu *et al.* (2019) [24]

stated that antibiotics affected the height of duodenum villi. After the prohibition of antibiotics for animal feed, the height of the duodenum villi of broilers in this study (Table 2) was 1813 - 2035 μm higher than 718.50- 992.00 μm Zavarize *et al.* (2012) [33] research. This finding showed that antibiotic-free feed improved total duodenum villi. The duodenal intervillous space in this finding was by Budiartawan *et al.* (2018) [8], i.e., 3.82 ± 1.07 - 4.01 ± 1.17 μm. The variance analysis showed that areas and climate did not significantly affect ($P>0.05$) height and duodenal intervillous space. Inter villous space is significantly affected by the chicken ageing, whereas the age of chickens in this study was relatively similar.

The histology of duodenum villi of broiler chickens aged 35-37 days in three different elevation area shown in Figure 1. Duodenum is small intestines with four layers, i.e., mucosa, submucosa, tunica muscular, and tunica serosa. Villi is the projection and distinctive feature of mucosa that absorbs nutrition, vitamin, and mineral and protects against pathogenic bacteria (Alshamy *et al.*, 2018) [2].

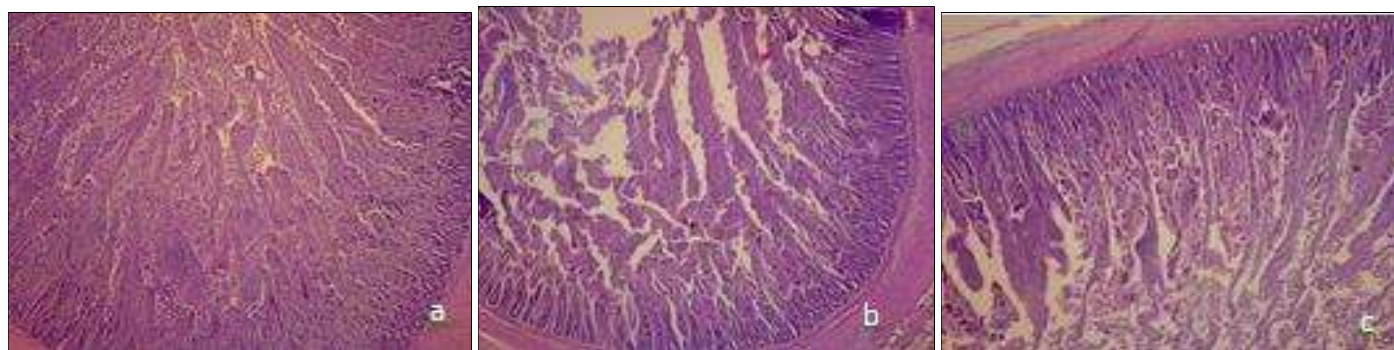


Fig 1: Histology of duodenum villi of broiler chickens kept in Lower elevation (a), Medium elevation (b) and High elevation (c)

Carcass yields

Table 3: Carcass yield

Area	Slaughter weight (g) ^s	Carcass weight (g) ^{ns}	Carcass percentage (%) ^{ns}
E1	1,608.00±149.23 ^a	1,002.00±60.25	62.40±2.433
E2	1,614.00±19.49 ^{ab}	1,064.00±129.15	65.91±5.52
E3	2,036.00±571.52 ^b	1,366.00±100.40	67.03±1.217

^{ns} the same superscripts within columns show no difference ($P>0.05$)

^s different superscripts within column show a significant difference ($P<0.05$)

Table 3 showed that slaughter weight and carcass percentage of broiler chickens aged 35-37 days in this research were relatively similar to broilers fed with antibiotics were around 1,746±36.5g (Miles *et al.*, 2006) [18] and 66.4% (Tayeri *et al.*, 2018) [29]. It showed that the bodyweight of all chickens across the three different elevation area was stable despite the absence of antibiotics in the feed. Jumiaty *et al.* (2017) [12] reported relatively similar slaughter weight with this study (1,707.13 ± 59.28 -1,867.25 ± 83.91g). The analysis of variance showed that the farming location significantly affected ($P<0.05$) slaughter weight, did not significantly affect ($P>0.05$) on carcass weight and carcass percentage. The slaughter weight of broiler chickens was different elevation areas due to different temperatures, humidity, and precipitation, which the chickens' welfare. According to Baracho *et al.* (2018) [6] and Baracho *et al.* (2019) [7], broiler welfare's contributing factors include temperature, humidity, and livestock. High environmental temperature is one of the challenges to the optimum performance of broiler chickens. Dharmawan *et al.* (2016) [9] stated that broiler chickens would experience high-temperature stress, causing a decrease in feed intake and slaughter weight.

Conclusion

The conclusion of this survey research was

1. Antibiotic-free broiler chickens have kept in an opened house with different elevation area, hold on normally digestive organs and carcass production. The crop, proventriculus, and liver's weight of chickens' broiler the same relatively. So, it is with the height of duodenum, and intervillous space.
2. A different elevation area produced slaughter weight, villi height, gizzard weight, and small intestine weight of broiler chicken differently

Acknowledgement

The authors express their attitude to the University of Jenderal Soedirman for funding the research through Superior Research Grant UNSOED year 2019.

References

1. Adedokun SA, Olojede OC. Optimizing gastrointestinal integrity in poultry: The role of nutrients and feed additives. *Front. Vet. Sci* 2019;5:348. <https://doi.org/10.3389/fvets.2018.00348>
2. Alshamy Z, Richardson KC, Hünigen H, Hafez HM, Plendl J. Comparison of the gastrointestinal tract of a dual-purpose to a broiler chicken line: A qualitative and quantitative macroscopic and microscopic study. *PLOS ONE* 2018;13(10):e0204921. <https://doi.org/10.1371/journal.pone.0204921>
3. Aluwong T, Sumanu VO, Ayo JO, Ocheja BO, Zakari FO, Minka NS. Daily rhythms of cloacal temperature in

- broiler chickens of different age groups administered with zinc gluconate and probiotic during the hot-dry season. *Physiol Rep* 2017; 5(12):e13314. DOI:10.14814/phy2.13314;
4. Al-Khalaifah HS. Benefits of probiotics and/or prebiotics for antibiotic-reduced poultry. *Poult. Sci* 2018;97(11):3807-3815. <https://doi.org/10.3382/ps/pey160>;
5. Anggitasari S, Sjoftan O, Irfan DIH. Effect of some kinds of commercial feed on quantitative and qualitative production performance of broiler chicken. *Buletin Peternakan* 2016;40(3):187-196. <https://doi.org/10.21059/buletinpeternak.v40i3.11622>;
6. Baracho MS, Nääs IA, Betin PS, Moura DJ. Factors that Influence the Production, Environment, and Welfare of Broiler Chicken: A Systematic Review. *Braz. J. Poultry Sci* 2018;20(3):617-624. <https://doi.org/10.1590/1806-9061-2018-0688>;
7. Baracho MS, Nääs IA, Lima NDS, Cordeiro AFS, Moura DJ. Factors Affecting Broiler Production: A Meta-Analysis. *Braz. J Poultry Sci* 2019;21(3):eRBCA--1052. <https://dx.doi.org/10.1590/1806-9061-2019-1052>;
8. Budiartawan Alit IK, Darmawan IGAC, Berata IK, Setiasih NLE. Perkembangan secara histologi vili duodenum ayam pedaging yang diberikan imbuhan asam butirir pada pakan. *Indonesia Medicus Veterinus* 2018, 522-530. <https://doi.org/10.19087/imv.2018.7.5.522>;
9. Dharmawan R, Prayogi HS, Nurgartiningih VMA. Penampilan produksi ayam pedaging yang dipelihara pada lantai atas and lantai bawah. *Jurnal Ilmu-Ilmu Peternakan* 2016;26(3):27-37. <https://doi.org/10.21776/ub.jiip.2016.026>;
10. Jannah PN, Sugiharto, Isroli. The effect of boiled turmeric water on the number of leukocyte and differentiation leukocyte of broilers. *Jurnal Ternak Tropika* 2017;18(1):15-19. <https://doi.org/10.21776/ub.jtapro.2017.018.1.3>;
11. Johnson TJ, Bonnie P. Youmans BP, Noll S, Cardona C, Evans NP *et al.* A consistent and predictable commercial broiler chicken bacterial microbiota in antibiotic-free production displays strong correlations with performance. *Applied and Environmental Microbiology* 2018;84(12):1-18. <https://doi.org/10.1128/AEM.00362-18>;
12. Jumiaty S, Nuraini, Aka R. Slaughter weight, carcass, gible and abdominal fat broiler chickens are given Curcumanthorhiza, roxb in the feed. *Jitro* 2017;4(3):1-9. <http://Dx.Doi.Org/10.33772/Jitro.v4i3>;
13. Kim S, Covington A, Pamer EG. The intestinal microbiota: Antibiotics, colonization resistance. *Immunol Rev* 2017;279(1):90-105. <https://doi.org/10.1111/imr.12563>
14. Kokoszyński D, Bernacki Z, Saleh M, Stęczny K, Binkowska M. Body conformation and internal organs characteristics of different commercial broiler lines. *Braz. J Poultry Sci* 2017;19(1):047-052. <https://doi.org/10.1590/1806-9061-2016-0262>;
15. Liermann W, Bochnia M, Berk A, Bösch V, Hüther L, Zeyner, and Dänicke S. Effects of feed particle size and hydro-thermal processing methods on starch modification, nutrient digestibility, and the performance and the gastrointestinal tract of broilers. *Animals (Basel)* 2019;9(6):294. <https://doi.org/10.3390/ani9060294>
16. Marlina AN, Zubaidah E, Sutrisno A. Pengaruh pemberian antibiotika saat budidaya terhadap keberadaan residu pada daging and hati ayam pedaging dari peternakan rakyat. *Jurnal Ilmu-Ilmu Peternakan*

- 2015;25(2):10-19.
<https://doi.org/10.21776/ub.jiip.2015.025.02.02>;
17. Masrianto, Arief II, Taufik E. Antibiotic Residue Analysis of Chicken Meat and Liver in Pidie Jaya, Aceh Province. *Jurnal Ilmu Produksi dan Teknologi Hasil Peternakan* 2019;07(3):102-110.
<https://doi.org/10.29244/jipthp.7.2.102-110>;
 18. Miles RD, Butcher GD, Henry PR, Littell RC. Effect of antibiotic growth promoters on broiler performance, intestinal growth parameters, and quantitative morphology. *J Poult. Sci* 2006;85:476-485. DOI:10.1093/ps/85.3.476;
 19. Mutibvu T, Chimonyo M, Halimani TE. Physiological responses of slow-growing chickens under diurnally cycling temperature in a hot environment. *Braz. J. Poultry Sci* 2017;19(4):567-576.
<https://doi.org/10.1590/1806-9061-2017-0485>;
 20. Nayak GD, Behura NC, Sardar KK, Mishra PK. Effect of climatic variables on production and reproduction traits of coloured broiler breeder poultry. *Vet. World* 2015;8(4):472-477. DOI: 10.14202/vetworld.2015.472-477
 21. Pilecky M, Schildberger A, Knabl L Orth-Holler D, Weber V. Influence of antibiotic treatment on the detection of *S. aureus* in whole blood following pathogen enrichment. *BMC Microbiol* 2019;19:180.
<https://doi.org/10.1186/s12866-019-1559-7>.
 22. Prakatur I, Miskulin M, Pavic M, Marjanovic K, Blazicevic V, Ivan Miskulin I *et al.* Intestinal morphology in broiler chickens supplemented with propolis and bee pollen. *Animals* 2019;9(301):1-12.
<https://doi.org/10.3390/ani9060301>;
 23. Purwinarto, Suprijatna E, Kismiati S. Effect of addition of cassava peel and lactic acid bacteria as feed additives on the digestive profile of broiler chicken. *JPI* 2020;22(1):101-109. DOI: 10.25077/jpi.22.1.101-109.2020;
 24. Qu H, Cheng Y, Chen Y, Li J, Zhao Y, Zhou Y. Effects of dietary zeolite supplementation as an antibiotic alternative on growth performance, intestinal integrity, and cecal antibiotic resistance genes abundances of broilers. *Animals (Basel)* 2019;9(11):909. DOI: 10.3390/ani9110909;
 25. Sari, Hafid H, Tasse AM. Kajian produksi carcass dan non carcass ayam kampung dengan pemberian ransum komersial tersubstitusi tepung kulit biji kedelai. *JITRO* 2016;3(3):67-80.
<http://dx.doi.org/10.33772/jitro.v3i3.2571>;
 26. Satimah S, Yuniarto VD, Wahyono F. Relative weight and small intestine length given feed composed of microparticle eggshell with supplemental probiotic *Lactobacillus* sp. *Jurnal Sains Peternakan Indonesia* 2019;14(4):396-403.
<https://doi.org/10.31186/jspi.id.14.4.396-403>;
 27. Shao D, Wang Q, Hu Y, Shi S, Tong H. Effects of cyclic heat stress on the phenotypic response, meat quality and muscle glycolysis of breasts and thighs of yellow-feather broilers, *Italian J Anim. Sci* 2019;18(1):301-308.
<https://doi.org/10.1080/1828051X.2018.1520051>;
 28. Tamzil MH. Stres panas pada unggas: Metabolisme, akibat dan upaya penanggulangannya. *Wartazoa* 2014;24(2):57-66. DOI:
<http://dx.doi.org/10.14334/wartazoa.v24i2.1049>;
 29. Tayeri V, Seidavi A, Asadpour L, Phillips CJC. A comparison of the effects of antibiotics, probiotics, synbiotics, and prebiotics on the performance and carcass characteristics of broilers. *Vet. Res. Commun* 2018;42(3):195-207. DOI: 10.1007/s11259-018-9724-2;
 30. Wang X, Farnell Y Z, Peebles ED, Kiess AS, Wamsley KGS, Zhai W. Effects of prebiotics, probiotics, and their combination on growth performance, small intestine morphology, and resident *Lactobacillus* of male broilers. *Poultry Sci* 2016;95:1332-1340.
<https://doi.org/10.3382/ps/pew030>;
 31. Yosi F, Widjastuti T, Setiyatwan H. Performance and physiological responses of broiler chickens supplemented with potassium chloride in drinking water under environmental heat stress. *Asian J Poult. Sci* 2017;11:31-37. <https://doi.org/10.3923/ajpsaj.2017.31.37>;
 32. Zaefarian F, Abdollahi MR, Cowieson A, Ravindran V. Avian Liver: The Forgotten Organ. *Animals* 2019; 9 (2): 63 DOI: 10.3390/ani9020063;
 33. Zavarize KC, Sartori J, Elisabeth G, Antonio P. Morphological changes of the intestinal mucosa of broilers and layers as affected by fasting before sample collection. *Rev. Bras. Ciênc. Aví* 2012;14:21-25. DOI:10.1590/S1516-635X2012000100004;
 34. Cândido MGL, Tinoco IDFF, Pinto FDD, Santos NT, Roberti RP. Determination of thermal comfort zone for early-stage broilers. *Engenharia Agrícola* 2016;36(5):760-767. <https://dx.doi.org/10.1590/1809-4430-Eng.Agric.v36n5p760-767/2016>.