



AGRICULTURAL ACADEMY



THE JOURNAL

Bulgarian Journal of Agricultural Science (BJAS)® is a peer-reviewed, open access, online and print journal, issued bimonthly.

It has been published in English since 1995.

ISSN 1310-0351 - print

ISSN 2534-983X - online

c/o Jusautor, Sofia

Publisher: Agricultural Academy of Bulgaria

Editor-in-Chief: Prof. Dr. **Martin Banov**

Executive editor: Vania Draganova (E-mail: bjas_sb@abv.bg)

Editor: Iliana Nikolova

Web: www.agrojournal.org

Address:

Bulgarian Journal of Agricultural Science

125, Tzarigradsko shosse Blvd., Block 1

1113 Sofia, Bulgaria

Print preparation: **Ivo Nikov**

Printing: **BPS Ltd**

REFERENCING AND INDEXING



The journal is ESCI indexed
(Web of Science)

Scopus SJR for 2021 – 0.25

Web of Science - Emerging Sources Citation Index

Scopus SJR for 2021 – 0.25

EBSCO - Academic Search Ultimate

AGRIS

CAB Abstracts

Google Scholar

SCOPE

BJAS publishes original research papers, review articles and brief communications from all areas of agricultural science including agricultural economics, agroecology, agrochemistry and soil science, crop science, plant protection, animal science, veterinary medicine, fisheries and aquaculture, agricultural engineering, food technologies and other related areas.

PROCEDURE FOR SUBMISSION

The journal publishes original articles, reviews and short communications that contain original experimental data or new interpretations of existing results. They must comply with the themes of the journal and have not been published elsewhere. Plagiarism is unacceptable for the journal. Use of foreign ideas and images in their original form is allowed only in their exact citation. All submitted articles are checked for plagiarism and when there are large parts already published texts or data, the articles are rejected. We do not accept manuscripts that are fully or partially published in other publications. The manuscript, written in English, should be submitted online after registration on the platform: www.agrojournal.org, the other possible way for the submissions is sending on the e-mail address: bjas_sb@abv.bg.

After the reception of the article, the manuscript is given to referees for anonymous peer review. Authors will be notified about the acceptance or rejection of the manuscripts. The editorial staff is not responsible for inaccurate citations, including the content of websites and copyright infringement. The publishing tax is Euro 12 per standard page.

SUBSCRIPTION

The subscription price is 200 EURO per year.

Editor-in-Chief

Prof. Dr. **Martin Banov** (Sofia - Bulgaria)

EDITORIAL BOARD

Cor. Member Prof. Eng. DSc **Stephan Dragoev** (Plovdiv – Bulgaria)

Prof. DSc **Irena Atanassova** (Sofia – Bulgaria)

Prof. DSc **Rositz Batchvarova** (Sofia – Bulgaria)

Prof. DSc **Radka Nedeva** (Shumen – Bulgaria)

Prof. Dr. **Anelia Katova** (Pleven – Bulgaria)

Prof. Dr. **Elena Todorovska** (Sofia – Bulgaria)

Prof. Dr. **Hrabrin Bachev** (Sofia – Bulgaria)

Contact Us

Note to contributors

From the beginning of 1995 the **Agricultural Academy** in Bulgaria is publishing **Bulgarian Journal of Agricultural Science (BJAS)®** - the first agricultural scientific journal in Bulgaria for fundamental and applied researches, published entirely in English language, and one of the few such journals in Central Europe. Bulgaria is an agricultural country with traditions and long standing experience in the development of agrarian science and production. BJAS, printing in English, in accordance with international standards, provides possibilities for Bulgarian agricultural science to enter adequately into the world's scientific field, to find its place in reviews, abstracts and electronic means for processing and transfer of scientific information. Besides scientific articles provided in Bulgarian universities and research institutes, BJAS publishes also articles from Eastern Europe and other countries all over the world. The Editorial board of the journal includes prominent scholars from Germany, United Kingdom, Austria, Italy, Spain, Japan, Greece, Bulgaria and other countries.

Prof. Dr. **Hristina Yancheva** (Plovdiv – Bulgaria)
Prof. Dr. **Hristo Daskalov** (Sofia – Bulgaria)
Prof. Dr. **Neli Valkova** (Chirpan – Bulgaria)
Prof. Dr. **Staiika Laleva** (Stara Zagora – Bulgaria)
Assoc. Prof. **Vesela Chalova** (Plovdiv – Bulgaria)
Prof. Dr. **Diego Rubales** (Cordoba – Spain)
Prof. Dr. **Nikolaos Katis** (Thessaloniki – Greece)
Prof. Dr. **Rainer Horn** (Kiel – Germany)
Prof. Dr. **Tu Quang Hien** (Thai Nguyen – Vietnam)
Prof. Dr. **Yalcin Kaya** (Edirne – Turkey)
Prof. Dr. **Yukihiro Sogimoto** (Kobe – Japan)
Prof. Dr. **Zichau Li** (Beijing – China)
Dr. **Giuseppe Sortino** (Palermo – Italy)
Dr. **Nicola Galluzzo** (Rieti – Italy)
Dipl.-Ing. **Klaus Wagner** (Vienna – Austria)

.....

Executive Editor

Vania Draganova

.....

Google търсене

☐ The Web ☒ www.agrojournal.org

Bulgarian Journal of Agricultural Science
125, Tsarigradsko shosse Blvd., Bl. 1, Room 214,
1113 Sofia, Bulgaria

For contacts:
Executive Editor Vania Draganova,
Phone: + 359 897 098 916



SDG search queries in Scopus

Find out more about Scopus

Use Scopus to identify research funders for each SDG & discover potential collaborations

Bulgarian Journal of Agricultural Science

FIND SIMILAR JOURNALS ?

options

Ads by Google

Stop seeing this ad

Why this ad?

1
**Journal of Central European
Agriculture**
HRV

43%

similarity

2
**Spanish Journal of
Agricultural Research**
ESP

39%

similarity

3
**Journal of Animal and Plant
Sciences**
PAK

37%

similarity

4
**Pertanika Journal of Tropical
Agricultural Science**
MYS

33%

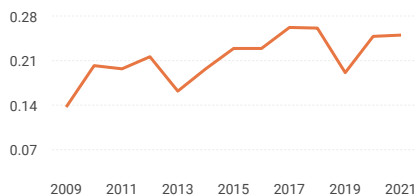
similarity

5
**Polish Journal of Natural
Sciences**
POL

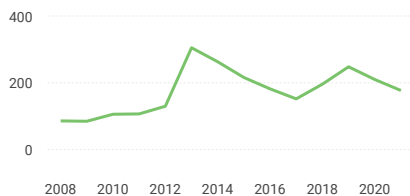
33%

similarity

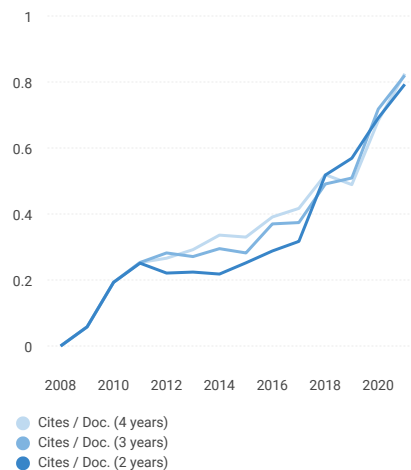
SJR



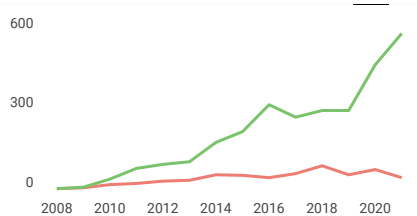
Total Documents



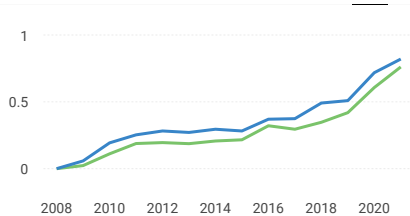
Citations per document



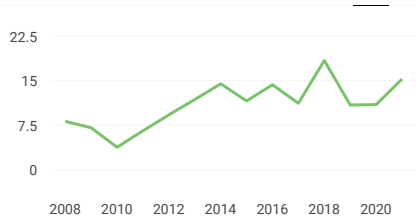
Total Cites Self-Cites



External Cites per Doc Cites per Doc

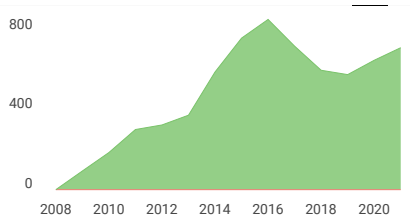


% International Collaboration



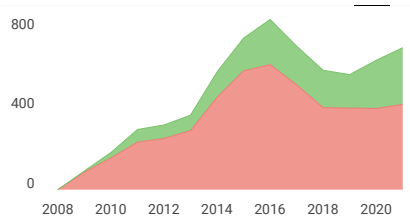
Citable documents

Non-citable documents



Cited documents

Uncited documents

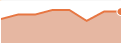

**Bulgarian Journal of
Agricultural Science**

Q3

Agricultural and
Biological Sciences
(miscellaneous)
best quartile

SJR 2021
0.25



powered by scimagojr.com

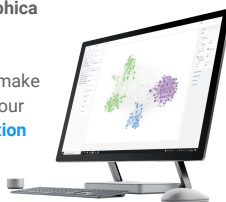
← Show this widget in
your own website

Just copy the code below
and paste within your html
code:

<a href="https://www.scima

SCImago Graphica

Explore, visually
communicate and make
sense of data with our
**new data visualization
tool.**



N **Nazar Rashid** 4 years ago

Dear Sir

I would like to ask about the period of publication in your esteemed jurnal and how much is the publishing fee and what are the conditions of publication.

Nizar Rashed Marza

PhD student

University of Kufa / Faculty of Agriculture

Iraq

[reply](#)

Leave a comment

Name

Email

(will not be published)

☐ I'm not a robot

reCAPTCHA

[Submit](#)

The users of Scimago Journal & Country Rank have the possibility to dialogue through comments linked to a specific journal. The purpose is to have a forum in which general doubts about the processes of publication in the journal, experiences and other issues derived from the publication of papers are resolved. For topics on particular articles, maintain the dialogue through the usual channels with your editor.

Developed by:



Powered by:



Follow us on [@ScimagoJR](#)

Scimago Lab, Copyright 2007-2022. Data Source: Scopus®

EST MODUS IN REBUS
Horatio (Satire 1.1.106)

[Cookie settings](#)

[Cookie policy](#)

Dear prof. Elly,

With regard to your submitted paper titled:

EFFECTIVENESS OF VARIOUS FEED SUPPLEMENT ON VILLI CHARACTERISTICS, FEED DIGESTIBILITY, AND LIVER-KIDNEY FUNCTION OF BROILER CHICKENS

We would like to kindly ask you to make some final minor corrections. Please find attached you paper, list of responses to reviewer's comments and the review file.
Thank you in advance

Vanya Draganova
Executive Editor
BJAS

Dear prof. Tugiyanti,

With reference to your request to publish your paper in BJAS next issue in June, we would like to inform you that we cannot proceed with your request as we have already finalized BJAS June issue. However, we might consider to include your paper in Issue 4 foreseen to be published in August.

Best regards,
Vanya Draganova
Executive Editor
BJAS

3:10

VoLTE 4G+ VoLTE 15%



Elly Tugiyanti May 26

Dear VanyaHere the payment.We hope you can continue to publish online in next August Please



Elly Tugiyanti 3:04 PM

Dear editor, we had send the APC a month agoCan you confirm it?



Bulgarian Journal 3:08 PM

to me ▾



Dear prof. Tugiyanti,

This is to confirm that your payment has been received.

Best regards,
Vanya Draganova
Executive Editor
BJAS



Elly Tugiyanti Yesterday
to Bulgarian ^



From Elly Tugiyanti • ellytugiyanti@gmail.com

To Bulgarian Journal • bjas_sb@abv.bg

Date May 26, 2022, 5:39 AM

[View security details](#)

Dear Vanya

Here the payment.

We hope you can continue to publish online in next August

Please reply this email

[Show quoted text](#)



Transfez-26...03036.pdf



Diteruskan

Dear Mrs. Tugiyanti,

We would like you to take our apologies for this late reply.
With regard to your submission we are glad to let you know that your paper titled:

EFFECTIVENESS OF VARIOUS FEED SUPPLEMENT ON VILLI CHARACTERISTICS, FEED DIGESTIBILITY, AND LIVER-KIDNEY FUNCTION OF BROILER CHICKENS

is going to be published in BJAS Journal issue 6-2022. The fee for publishing is going to be 212 Euro. If you wish us to proceed with the publishing, please send us the following information so that we can issue a pro forma invoice.

- receiver name
- organisation name
- address - country, city, street number
- personal number - could be a date of birth or VAT number

Thank you for your assistance.

Vanya Draganova
Executive Editor
BJAS

Effectiveness of various feed supplement on villi characteristics, feed digestibility, and liver-kidney function of broiler chickens

Elly Tugiyanti^{1*}, Emmy Susanti² and Soegeng Heriyanto³

¹University of Jenderal Soedirman, Department of Animal Production, Faculty of Animal Science, Purwokerto, Indonesia 53123

²University of Jenderal Soedirman, Department of Animal Nutrition, Faculty of Animal Science, Purwokerto, Indonesia 53123

³University of Wijayakusuma, Department of Animal Production, Faculty of Animal Science, Purwokerto, Indonesia 53152

*Correspondence: ellytugiyanti@gmail.com

Source of Fund: Universitas Jenderal Soedirman for funding the research through Applied Leading Research Grant UNSOED in 2020, with Decree No: 118/UN23.18/PT.01.05/2020.

Abstract

Tugiyanti, E., Susanti, E. & Heriyanto, S. (2022). Effectiveness of various feed supplement on villi characteristics, feed digestibility, and liver-kidney function of broiler chickens. *Bulg. J. Agric. Sci.*, 28 (5), 911–917

The research aimed to identify the effect of different feed supplements on the morphometry of duodenum villi, the protein and fat digestibility, and liver and kidney function of broilers. The study used 180 unisex DOCs with an initial body weight of 40.40 ± 2.85 g. The experimental study was conducted in a Completely Randomized Design with six feed supplement treatments, i.e., the non-supplemented feed (negative control), antibiotic (positive control), probiotic, acidifier, phytobiotic, and combined feed supplements. Each treatment was replicated six times. The result showed that feed incorporated with different additives had a highly significant effect ($P < 0.01$) on the morphometry of duodenum villi (length, width, and crypt depth); a non-significant effect ($P > 0.05$) on metabolic energy and protein and fat digestibility of broilers, and a significant effect ($P < 0.05$) on the level of serum glutamic oxaloacetic transaminase and serum glutamic pyruvic transaminase (SGOT and SGPT), uric acid, creatinine, ureic, and blood albumin. Conclusively, feed supplements consisted of probiotics, acidifiers, probiotics, and their combinations have increased the size of duodenum villi, and the performance of liver and kidneys of broilers much better than antibiotics alone. Although, this study reported found that these supplements could not increase protein and fat digestibility.

Keywords: broiler chickens; feed digestibility; feed supplements; liver and kidney function; duodenal villi

Introduction

Broiler meat in Indonesia contributes as high as 71.49% to national meat production (Directorate General of Livestock and Animal Health, 2020) due to technology manipulation that allows shorter maintenance. Broilers are generally harvested at 4-5 weeks old with an average body weight of 1550–2020

g/head. The high performance of broilers cannot be separated from feed quality and digestibility, as well as the performance of duodenal villi without causing disorder in the liver and kidney function nor residue in the meat. The characteristics of modern broilers are fast growth and high body fat; therefore, they need a proper level of feed protein and fat. Also, quality feed has a high digestibility (Arifin & Pramono, 2016; Bryan & Classen, 2020).

There have been many types of feed supplements for broilers, especially after using antibiotics as a growth promoter was banned. Feed producers and famers have attempted many self-mixing to create a substitute for antibiotics that can gain feed efficiency (Wiradimadja et al., 2018). The tropical wet climate in Indonesia allows high temperature and humidity throughout the year, so it takes feed supplement to support the high performance of broilers. The popular feed supplements include probiotics, acidifier, phytobiotic, and the combination of probiotic, acidifier, and phytobiotic. Probiotic is offered to broilers to improve growth, feed digestibility, and body immune. There have been many probiotic products containing microbes, such as *Lactobacillus* sp., *Rhodopseudomonas* sp., *Actinomyces* sp., *Streptomyces* sp., *Bacillus Subtilis*, and yeast (Abdurrahman & Yanti, 2018). Acidifiers in feed maintain the balance of microbes in the digestive tract by maintaining the pH, thus improving protein absorption (Yendy et al., 2014; Abdurrahman & Yanti, 2018). Feed supplements to substitute antibiotics should not render toxicity in chickens (Akbar & Hari, 2017).

Feed supplements to substitute antibiotics should not render toxicity in chickens (Kendran et al., 2017). Feed supplement has its advantages and drawbacks; therefore, its effectiveness on duodenum, digestibility, and the function of liver and kidneys in broilers needs to investigate.

This study aims to identify the effectiveness of different feed supplements to improve the performance of duodenal villi, liver, and kidney function. The effect of protein and fat digestibility was investigated.

Materials and Methods

Animals and supplements

The materials in this study were 180 DOCs unisex broilers (40.40±2.85 g initial BW) previously vaccinated with live Newcastle Disease (ND), IB-ND KV, and transmute IBD. Broilers were randomly allotted to individual cages 60x60X35 cm, five chickens each. The basal feed was commercial feed, while the supplement consisted of (1) antibiot-

ics, (2) probiotic, (3) acidifier, (4) phytobiotic (garlic, ginger, and turmeric combined), (5) combined of feed supplements of probiotic, acidifier, and phytobiotic. All feed supplements in form of powder were incorporated into the commercial feeds. Table 1 presents the nutrient content of the feed supplement.

The antibiotics contains 25 mg/kg feed tetracyclines HCl, and the probiotic (2.5g/kg feed) contained (5.4×10^7 cfu/g *Lactobacillus* sp. and 2.3×10^8 cfu/g *Bacillus* sp). The acidifier contained 450 g fumaric acid, 195 g lactic acid, 10 g citric acid, 2 g/kg feed propionic and formic acids. The phytobiotics were composed of 200 g garlic, 400 g turmeric powder, 400 g ginger powder, and offered to broilers as much as 1 g/kg feed. The combined of feed supplements were composed of 0.83 g/kg feed probiotic (33.33% probiotics level), 0.67 g/kg feed acidifier (33.33% acifier level), and 0.33 g/kg feed phytobiotic (33.33% phytobiotics level). The supplements in this study are commercial feed supplements commonly used by the famers after the prohibition of antibiotics. The dosage of supplementation followed that printed on the label of each supplement.

Experimental Design

The researchers experimented with a Completely Randomized Design, using six treatments of feed supplements, namely non-supplement (negative control), antibiotics (positive control), probiotics, acidifier, phytobiotic, and combined feed supplements. Each treatment contained five broilers and had six replicates.

The broilers were offered commercial feed/basal feed for ten days. Before treatments were offered, a preliminary phase conducted for four days fed the broilers with 25% treatment feed + 75% commercial feed (Day 1), 50% treatment feed + 50% commercial feed (Day 2), 75% treatment feed + 25% commercial feed (Day 3), 100% treatment feed since Day 4 onwards.

The treatments were offered when the broilers reached the age of 14 through 35 days. Feed and drinking water were provided ad libitum, feed intake was recorded daily,

Table 1. Nutrient content of treatment feed

Treatments	Water, %	Crude protein, %	Crude lipid, %	Crude fiber, %	Ash, %
Basal feed	13.67	20.30	5.64	5.42	6.89
Basal feed+ Antibiotic	13.60	20.30	5.62	5.42	6.88
Basal feed+ Probiotic	13.85	20.34	5.80	5.38	7.02
Basal feed+ Acidifier	13.66	20.30	5.60	5.45	6.89
Basal feed+ Phytobiotic	13.82	20.32	5.76	5.42	7.02
Basal feed+ (probiotic, acidifier, and phytobiotic combined)	13.86	20.36	5.72	5.39	6.81

Note: The result of proximate analysis of Laboratory of Nutrition and Feed of Animal Science Faculty, Jenderal Soedirman University (2019)

and body weight was measured once a week. The temperature and humidity of the cage were measured in the morning, midday, and afternoon. When the broilers were 35 days old, blood samples were drawn from the brachialis vein of the chickens in each unit to obtain data on liver and kidney function. Then, the broilers were slaughtered, the carcass was weighed, and the duodenum was removed to observe the villi. The obtained data were subjected to the analysis of variance, and any significant effects were followed up with the Dunnett test.

Creating Histology Microscope Slide and Measuring the Duodenal Villi

The histology microscope slide was created based on a method by Zainuddin et al. (2016) where the small intestines were removed after the bird was slaughtered. The small intestines were stretched, and the duodenum was cut and washed from fat and feed residue using 0.9% physiological NaCl. The histology microscope slide was created using Hematoxylin Eosin (HE). Duodenum sampled was cut 2-cm long, fixated in 10% neutral buffer formalin, and let soak for 24-48 hours. The samples were dried and dehydrated by soaking into 80%, 90%, and 100% alcohol and absolute alcohol with two replications, two hours each. The next step, or clearing, put the samples into xylol for 30 minutes and repeated three times.

Following the clearing process, the sample was infiltrated by soaking the samples in infiltration paraffin for 30 minutes and repeated three times in different paraffin. Then, the samples were embedded in a paraffin block and let sit for at least 24 hours before the cutting and coloring process. In the last step, which is coloring, the samples were sliced using a 4 μ m microtome, placed on a glass object, and HE-colored. The microscope slide was covered with glass-covered and sealed with adhesive tape. The ready slides in glass objects were observed and measured using a computer-aided microscope.

The intestinal villi were measured using a method by Iji et al. (2001), namely a) villi height (μ m) by measuring the highest distance from the villi; b) villi width (μ m) by measuring the apical width and basal width, and averaged. c) The crypt depth (μ m) by measuring the deepest crypt depth.

Measuring the digestibility of protein and fat digestibility

The digestibility of protein and fat was measured when the broilers were 35 days old using a total collection method for seven days. Broilers with similar weights were selected from each treatment. The feces collected in a container was sprayed with HCl 0.2 N every three hours to prevent the N evaporation and then weighed. The feces were sun-dried to obtain the air-dried weight, then oven-dried at 60°C for 24 hours to get the dry weight. Ten percent of the sample was

taken to analyze the crude protein (Kjeldahl method) and crude fat (Soxhlet method). Protein or fat digestibility is the amount of digested protein or fat that is expressed in percent or calculated using a formula by Anggorodi (1995).

The analysis of liver and kidney function

The blood sample was drawn when the broilers were 35 days old from the brachialis vein to obtain the data of liver and kidney function. The blood sample was centrifuged at 3000 rpm speed for 10-15 minutes. The data of liver function was analyzed for SGOT (serum glutamic oxaloacetic transaminase) and SGPT (serum glutamic pyruvic transaminase) activities in the serum using an Auto analyzer (Refloton (R) plus). A drop of blood was placed on a kit slide for each parameter and inserted into an AutoAnalyzer. The automated reading was ready after a few minutes.

Data on kidney function was obtained by examining the uric acid, creatinine, ureic, and albumin. As much as 20 μ L serum for each variable was added with a solution of reagent 1 (buffer) and reagent 2 (starter) using different types of a reagent according to the variables. The serum and reagent were mixed, and the automated reading was performed by the Auto-analyzer Cobas Mira Instrument DIRUI BCC-30000. The analysis used a Biocon Diagnostic MCD-900 test kit quantitatively. Data on kidney function was obtained by examining the uric acid, creatinine, ureic and albumin. As much as 20 μ L serum for each variable was added with a solution of reagent 1 (buffer) and reagent 2 (starter) using different types of reagent according to the variables. The serum and reagent were mixed, and the automated reading was performed by the Auto-analyzer Cobas Mira Instrument DIRUI BCC-30000. The analysis used a Biocon Diagnostic MCD-900 test kit quantitatively.

Results and Discussion

Characteristics of Duodenal Villi

The small intestine is the main place for chickens to digest and absorb nutrients (Zhang & Chen, 2019). The anatomy of the small intestines is divided into three parts: duodenum, jejunum, and ileum. In broilers, the duodenum is the smallest part with the biggest diameter in the intestine and a circular mucosa fold (Zainuddin et al., 2014). It performs chemical digestion on food with the help of digestive enzymes which are mostly derived from the pancreas, and the villi are longer than the jejunum and ileum (Metzler-Zebeli et al., 2018). The longer the intestinal villi, the broader the surface for optimum nutrient absorption (Satimah et al., 2019). The size of duodenal villi of broilers consuming feed supplement to substitute antibiotics is presented in Table 2.

Table 2. The size of chicken duodenal villi

Treatments	Villi length, μm	Villi width, μm	Crypt depth, μm
Basal feed (negative control)	530.23 \pm 15.73a	101.29 \pm 4.52a	42.48 \pm 2.93a
Basal feed+ Antibiotic (positive control)	497.02 \pm 32.28a	93.27 \pm 4.575a	38.61 \pm 2.61a
Basal feed+ Probiotic	547.54 \pm 21.21b	101.92 \pm 2.77a	50.65 \pm 2.62b
Basal feed+ Acidifier	602.84 \pm 9.97b	117.42 \pm 4.15b	48.53 \pm 5.61b
Basal feed+ Phytobiotic	732.268 \pm 18.97c	101.54 \pm 6.50a	51.05 \pm 1.68b
Basal feed+ Combined feed supplements	724.96 \pm 12.83c	104.42 \pm 4.87a	51.86 \pm 2.73b

Note: Different superscripts within column show a highly significant difference (<0.01)

Table 3. Metabolizable energy value, protein and lipid feed digestibility of broiler fed treatments

Treatments	Protein digestibility, %	Fat digestibility, %
Basal feed (negative control)	82.77 \pm 3.84	70.54 \pm 3.78
Basal feed+ Antibiotic (positive control)	82.08 \pm 1.69	72.81 \pm 2.36
Basal feed+ Probiotic	84.50 \pm 2.02	71.04 \pm 2.51
Basal feed+ Acidifier	85.83 \pm 1.58	72.97 \pm 1.12
Basal feed+ Phytobiotic	84.88 \pm 2.24	71.46 \pm 1.68
Basal feed+ combined feed supplement	86.68 \pm 3.59	70.47 \pm 2.61

Table 2 shows that feed incorporated with different supplements had a highly significant difference ($P<0.01$) on villi morphometric (length, depth, and crypt depth) of broilers' duodenum. Meanwhile, the non-supplemented feed fortified with antibiotics had the same effect on the length and width of duodenal villi. The dose of antibiotics incorporated in the feed could inhibit the pathogenic bacteria but created residuals that blocked the epithelial. Therefore, it could not stimulate the development of villi length and depth and the crypt depth of the duodenal villi. In contrast, acidifier, phytobiotic,

and the combined feed supplements could inhibit the pathogenic bacteria and stimulate the development of villi (villi length and width and crypt depth) (Table 3).

The acidifier and the active compounds in the phytobiotic (allicin, curcumin, ingenol, and shogaol) exhibit high bactericidal and antivirus properties and positive effect on regulating the population of the intestinal bacteria (Leeson et al., 2005; Adil et al., 2010). The essential oil in garlic, turmeric, and ginger can be used as natural antibiotics because it can inhibit pathogenic bacteria (Adli et al., 2019). In a proper amount, probiotics as living organisms would reduce the population of pathogens in the intestinal and contributes positively to the digestive system (Hamida et al., 2015). Probiotics can increase the lactic acid bacteria in the chicken intestines, and garlic, turmeric, and ginger can balance the non-pathogenic bacteria and lower the level of pathogenic bacteria (Sjofjan et al., 2020).

Duodenum consists of four layers, tunica mucosa, submucosa, muscular, and serosa. The mucosa consists of a) columnar epithelial, and between the cells are goblet cells, b) lamina propria, and c) muscularis mucosa. Tunica mucosa has intestinal villi, the submucosa is a connective tissue with many blood vessels and lymph, and tunica muscularis

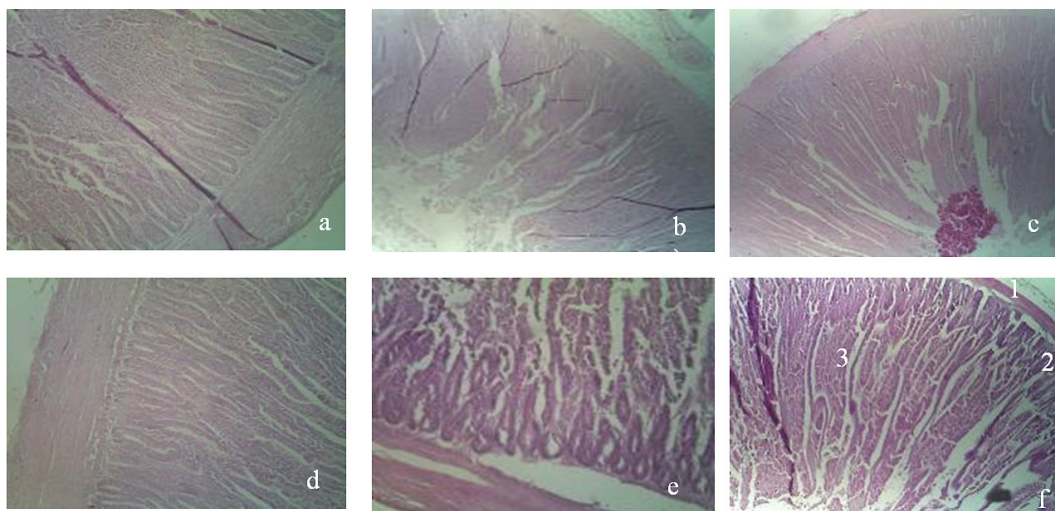


Fig. 1. Histology of duodenal villi of each treatment:
a) non-feed supplement, b) antibiotic, c) probiotic, d) acidifier, e) phytobiotic and f) combined treatments.
1. Tunica serosa
2. Tunica muscularis
3. Tunica mucosa

are smooth muscles composed as fibers. Liberkuhn duodenal gland, composed of linear cylindrical epithelial cells, produces mucus and some enzymes for peptide, carbon dioxide, and fat. Liberkuhn gland culminates in the crypt in the intestinal villi (Mardhiah, 2015) as presented in Figure 1.

Protein and fat digestibility

Digestible nutrients are defined as the proportions that are not excreted in feces or assumedly absorbed by the broilers. The digestibility of protein and fat of broilers are $64.60 \pm 11.91\%$ and $77.02 \pm 10.40\%$, respectively (Andriyanto et al., 2016).

The present study demonstrates that feed supplements do not significantly affect ($P > 0.05$) the energy metabolism and digestibility of protein and fat. Feed supplement treatments (antibiotics, probiotics, phytobiotic, and acidifiers) can kill pathogenic bacteria without damaging the membranes of digestive tracts but thinning the cell wall; consequently, it improves the intestines absorbability of feed substances that the body needs. This study observed that either antibiotic treatments or other treatments had a similar effect on protein and fat digestibility. However, the side effects of antibiotics include the increased villi density and length as well as the intestinal surface because antibiotics kill both pathogenic and commensal bacteria, thus decreasing the function of small intestines and nutrient digestibility (Murugesan et al., 2015; Zhang & Chen, 2019). Furthermore, antibiotics hamper the development of chicken by inhibiting (1) DNA replication, (2) ribonucleic acids (RNA) and protein synthesis, (3) cell division, differentiation, and development, (4) folic acid metabolism, or (5) membrane cells and the synthesis of microorganisms in cell walls that are responsible for the infection spread (Mund et al., 2017). Incorporating probiotics and organic acid (acidifier) in drinking water or feed of broilers is increasing the absorption by improving the performance of digestive enzymes so it affects the increased digestibility and absorption of substances, especially fiber and protein (Hume, 2011; Pio et al., 2017). Phytogenic feed additives are the accepted alternative strategy to enhance animal performance because phytogenic feed additives exhibit antibacterial, antifungal, antioxidant, and anti-inflammatory properties that altogether improve broiler performance (Hai et al., 2020; Candinegara, 2020).

Liver-Kidney Function

The liver and kidney are vital organs for detoxification and secretion. The chemo tactical factor and chemical compounds would lead to degeneration and necrose in the liver and kidneys characterized by the accumulation of monocyte cells (Sugito et al., 2007; Mardhiah 2015).

Table 4 shows that feed incorporated with different feed supplements significantly affected ($P < 0.05$) the Serum Glutamic Oxaloacetic Transaminase (SGOT), and Serum Glutamic Pyruvic Transaminase (SGPT) of broilers. The SGOT and SGPT of broilers identified in this study is within the normal range which, according to Kiran et al. (2015), is $58.5 \mu\text{g/mL}$ and $24.40 \mu\text{g/mL}$, respectively. The SGOT and SGPT of broilers offered with antibiotics-supplemented feed were different from those with non-supplemented feed or supplemented with probiotic, acidifier, phytobiotic, and the combined supplements. Accordingly, the antibiotic-supplemented feed would increase the work of the liver and potentially damages the hepatic cells. It confirms a previous study (Butaye et al., 2003) that when a low dose of antibiotic is absorbed regularly, in the long run, would damage the liver whose vital function is detoxification of toxic substance.

Table 4. The function of broiler's liver offered with supplemented feed

Treatments	SGOT, μL	SGPT, μL
Basal feed (negative control)	$19.43 \pm 3.65\text{a}$	$34.67 \pm 5.22\text{a}$
Basal feed+ Antibiotic (positive control)	$29.18 \pm 4.52\text{b}$	$56.76 \pm 5.19\text{b}$
Basal feed+ Probiotic	$19.26 \pm 2.82\text{a}$	$39.69 \pm 5.32\text{a}$
Basal feed+ Acidifier	$22.46 \pm 6.11\text{a}$	$39.69 \pm 9.48\text{a}$
Basal feed+ Phytobiotic	$22.46 \pm 4.79\text{a}$	$36.98 \pm 6.44\text{a}$
Basal feed+ combined feed supplement	$22.21 \pm 5.23\text{a}$	$35.93 \pm 4.56\text{a}$

Note: Different superscript within column shows significant difference ($P < 0.05$)

Recent studies on the influence of organic acids, probiotics, phytobiotic as a growth promoter for broiler chickens reported that the supplements did not increase SGOT and SGPT because they could decimate the pathogenic bacteria and inhibit bacteria translocation from the intestines to the other organs, thus reducing the liver inflammation (Winarsih et al., 2008; Al-Saad et al., 2014; Habibu et al., 2018; Taer et al., 2020).

The main function of the kidney is excreting the Non-protein Nitrogen Compound (NPN) which is the by-product of the body metabolism of nucleic acid, amino acid, and protein including urea, creatinine, and uric acid (Imtiaz et al., 2020; Maiuolo et al., 2016; Verdiansah, 2016). The level of uric acid, creatinine, ureic, and albumin of broilers according to Ding et al. (2020) are $199.76 \pm 21.29 \mu\text{mol/L}$, $9.16 \pm 1.57 \mu\text{mol/L}$, $0.71 \pm 0.20 \mu\text{mol/L}$, and $9.16 \pm 1.57 \text{g/L}$, respectively. This study reported a lower level of those substances, namely 3.26 ± 0.02 – $4.42 \pm 0.65 \text{mg/dL}$, 2.34 ± 0.06 – $3.80 \pm 0.04 \text{mg/dL}$, 3.72 ± 0.17 – $4.64 \pm 0.94 \text{mg/dL}$, and 1.45 ± 0.45 – $3.88 \pm 0.82 \text{g/dL}$, respectively.

Table 5. Kidneys function of broilers offered with supplemented feed

Treatments	Uric acid, mg/dL	Creatinine, mg/dL	Ureic, mg/dL	Albumin, g/dL
Basal feed (negative control)	3.29±0.02a	2.34±0.06a	3.82±0.22a	1.45±0.45a
Basal feed+ Antibiotic (positive control)	4.42±0.65b	3.80±0.04b	4.64±0.94b	3.88±0.82b
Basal feed+ Probiotic	3.26±0.02a	2.40±0.11a	3.75±0.35a	1.56±0.21a
Basal feed+ Acidifier	3.33±0.04a	2.36±0.02a	3.72±0.17a	1.62±0.53a
Basal feed+ Phytobiotic	3.34±0.12a	2.40±0.18a	3.77±0.34a	1.57±0.20a
Basal feed+ combined feed supplement	3.35±0.12a	2.41±0.24a	3.78±0.12a	1.76±0.28a

Note: different superscripts within column show significant difference ($P < 0.05$)

Our study demonstrated that the feed supplement significantly affected ($P < 0.05$) the level of uric acid, creatinine, ureic, and albumin in the blood of broilers (Table 5). The accumulated antibiotics have a nephrotoxic effect derived from cationic amino that can damage the proximal tubular epithelial cells in the kidneys by binding the phosphoinositide; as a result, the filter process is inhibited and the level of uric acid, creatinine, ureic, and albumin increase (Pazhayattil & Shirali, 2014). The increased ureic, creatinine, and albumin is indicative of the declining function of kidneys (Verdiansyah, 2016).

Antibiotics tend to deteriorate kidneys' function as demonstrated by the high level of uric acid, creatinine, ureic, and albumin. It is because antibiotics not only fight the infectious bacteria but also kill all bacteria; consequently, it disturbs the livestock health, especially the liver and kidneys function (Hume, 2011; Śliżewska et al., 2019). It is recommended to use the common alternative of feed additives, such as probiotics, prebiotic, enzymes, organic acids, immunostimulants, bacteriocin, bacteriophage, photogenic, phytoncides, nanoparticles, and essential oils. The alternative feed additives are safer because they improve the broiler's performance without disturbing kidney function nor leaving residual traces in the meat, liver, kidneys, skin, and fat (Mehdi et al., 2018; Habibu et al., 2018).

Conclusion

Feed supplement alternatives (probiotics, acidifier, and phytobiotics) could improve the size of duodenal villi and the performance of liver and kidney in broilers better than antibiotics, although it could not increase the digestibility of protein and fat.

Acknowledgements

The authors express their attitude to Universitas Jenderal Soedirman for funding the research through Applied Leading Research Grant UNSOED in 2020, with Decree No: 118/UN23.18/PT.01.05/2020.

Conflicts of Interest

The authors declare no conflict of interests

References

- Abdurrahman, H. Z. & Yanti, Y. (2018). An overview of probiotics and prebiotics effects on chicken meat quality. *J. Trop. Anim. Prod.*, 19 (2), 95–104. <https://doi.org/10.21776/ub.jta-pro.2018.019.02.4>.
- Adil, S., Bandy, T., Bhat, G. A., Mir, M. S. & Rehman, M. (2010). Effect of dietary supplementation of organic acids on performance, intestinal histomorphology, and serum biochemistry of broiler chicken. *Vet. Med. Int.*, 4, 479–85. <https://doi.org/10.4061/2010/479485>.
- Adli, D. N., Chi, Y., Lee, J. W. & Sjöfjan, O. (2019). Supplementation mannan-rich fraction (mrf) and/or combination with probiotic-enhanced water acidifier on dietary female broiler at 28 days as natural growth promoters (NGPs). *Int. Res. J. Adv. Engin. Sci.*, 4 (3), 424–26. <http://doi.org/10.5281/zenodo.3459284>.
- Akbar, M. & Hari, P. M. E. (2017). The effect of supplementing turmeric extract (*Curcuma longa* L.) and Curcuma (*Curcuma xanthorrhiza* Roxb.) into the water on the performance of male quails. *Jurnal Fillia Cendikia*, 2 (2), 8–16. <http://ejournal.fp.uniska-kediri.ac.id/>.
- Al-Saad, S., Abbod, M. & Yones, A. A. (2014). Effects of some growth promoters on blood hematology and serum composition of broiler chickens. *Int. J. Agric. Res.*, 9 (5), 265–70. <https://doi.org/10.3923/ijar.2014.265.270>.
- Andriyanto, A. S., Satyaningtjias, Yufiandri, R., Wulandari, R., Darwin, V. M. & Siburi, S. N. A. (2016). Broiler chicken performances and feed digestibility treated with multi-dose testosterone hormone. *Acta Vet. Indones*, 3 (1), 29–37. <https://doi.org/10.29244/avi.3.1.29-37>.
- Anggitasari, S., Sjöfjan, O. & Djunaidi, I. H. (2016). Effect of some kinds of commercial feed on quantitative and qualitative production performance of broiler chicken. *Buletin of Animal Science*, 40 (3), 187–96. <https://doi.org/10.21059/buletinpeter-nak.v40i3.11622>.
- Bryan, D. D. S. L. & Classen, H. L. (2020). *In vitro* methods of assessing protein quality for poultry. *Animals*, 10 (4), 1–19. <https://doi.org/10.3390/ani10040551>.
- Butaye, P., Devriese, L. A. & Haesebrouck, F. (2003). Antimicrobial growth promoters used in animal feed: effects of less well known antibiotics on gram-positive bacteria. *Clin. Microb. Rev.*, 16 (3), 175–88. <https://doi.org/10.1128/cmr.16.2.175-188.2003>.

- Candinegara, T.** (2020). Challenges of using feed additives in Indonesia. *IOP Conference Series: Earth and Environmental Science*, 492 (1), 1–7. <https://doi.org/10.1088/1755-1315/492/1/012001>.
- Ding, J., He, S., Xiong, Y., Liu, D., Dai, S. & Hu, H.** (2020). Effects of dietary supplementation of fumaric acid on growth performance, blood hematological and biochemical profile of broiler chickens exposed to chronic heat stress. *Rev. Bras. Cienc. Avic.*, 22 (1), 1–8. <https://doi.org/10.1590/1806-9061-2019-1147>.
- Directorate General of Livestock and Animal Health** (2020). Statistics of Livestock and Animal Health 2020. Directorate General of Livestock and Animal Health. Ministry of Agriculture of the Republic of Indonesia. Jakarta. <https://ditjenpkh.pertanian.go.id>.
- Hai, PV, Hung PHS, Dung HT, Duc LM, Khuong DTT, Liem TN** (2020). Effect of dietary supplementation of ethanol extract of chives and ginger on the productivity and health performance of broilers. *Hue University Journal of Science: Agric. and Rur. Dev.*, 129 (3C), 1–13. <https://doi.org/10.26459/hueunijard.v129i3C.5881>.
- Hume, M. E.** (2011). Historic perspective: prebiotics, probiotics, and other alternatives to antibiotics. *Poult. Sci.*, 90 (11), 2663–69. <https://doi.org/10.3382/ps.2010-01030>.
- Iji, P., Choct, M., Hughes, R. J. & Tivey, D.** (2001). Intestinal structure and function of broiler chickens on wheat-based diets supplemented with a microbial enzyme. *Asian- Aust. J. Anim. Sci.*, 14 (1), 54–60.
- Kendran, A. A. S., Arjana, G. A. A. & Pradnyantari, A. A. S. I.** (2017). The activities of alanine aminotransferase and aspartate aminotransferase enzymes in male white rats treated with extract areca nut treatment. *Bul. Vet. Udayana*, 9 (2), 132–138. <https://doi.org/10.21531/bulvet.2017.9.2.132>.
- Leeson, S., Namkung, H., Antongiovanni, M. & Lee, E. H.** (2005). Effect of butyric acid on the performance and carcass yields of broiler chickens. *Poult. Sci.*, 84 (9), 1418–22. <https://doi.org/10.1093/ps/84.9.1418>.
- Maiuolo, J., Oppedisano, F., Gratteri, S., Muscoli, C. & Molace, V.** (2016). Regulation of uric acid metabolism and excretion. *Int. J. Cardiol.*, 213, 8–14. <https://doi.org/10.1016/j.ijcard.2015.08.109>.
- Mardhiah, A.** (2015). Comparisional study of the histology of the small and coard intoes between partridges (*Gallus gallus*) and coarse chicken (White leghorn). *Jesbio*, IV (1), 32–36.
- Mehdi, Y., Létourneau-Montminy, M. P., Gaucher, M. L., Chorf, Y., Suresh, G., Rouissi, T., Brar, S. K., Côté, C., Ramirez, A. A. & Godbout, S.** (2018). Use of antibiotics in broiler production: global impacts and alternatives. *Anim. Nut.*, 4 (2), 170–78. <https://doi.org/10.1016/j.aninu.2018.03.002>.
- Metzler-Zebeli, B. U., Magowan, E., Hollmann, E., Ball, M. E. E., Molnar, A., Witter, K., Ert, R., Hawken, R. J., Lawlor, P. G., O'Connell, N. E., Aschenbach, J. & Zebeli, Q.** (2018). Differences in intestinal size, structure, and function contributing to feed efficiency in broiler chickens reared at geographically distant locations. *Poult. Sci.*, 97, 578–91. <https://doi.org/http://dx.doi.org/10.3382/ps/pex332>.
- Mund, M. D., Khan, U. H., Tahir, U., Mustafa, B. E. & Fayyaz, A.** (2017). Antimicrobial drug residues in poultry products and implications on public health: A Review. *Int. J. Food Prop.*, 20 (7), 1433–46. <https://doi.org/10.1080/10942912.2016.1212874>.
- Murugesan, G., Syah, S. B. A., Haldar, S. & Pender, C.** (2015). Phytogenic feed additives as an alternative to antibiotic growth promoters in broiler chickens. *Front. Vet. Sci.*, 2 (21), 1–6. <https://doi.org/10.3389/fvets.2015.00021>.
- Pazhayattil, G. S. & Shirali, A. C.** (2014). Drug-induced impairment of renal function. *Int. J. Nephrology and Renovascular Disease*, 7, 457–68. <https://doi.org/10.2147/IJNRD.S39747>.
- Satimah, S., Yunianto, V. D. & Wahyono, F.** (2019). Relative weight and small intestine length given feed composed of microparticle egg shell with supplemental probiotic *Lactobacillus* Sp. *J. sain peternak*, 14 (4), 21–25. <https://doi.org/https://doi.org/10.31186/jspi.id.14.4.396-403>.
- Śliżewska, K., Cukrowska, B., Smulikowska, S. & Cielecka-Kuszyk, J.** (2019). The effect of probiotic supplementation on performance and the histopathological changes in liver and kidneys in broiler chickens fed diets with Aflatoxin B1. *Toxins*, 11 (2), 1–15. <https://doi.org/10.3390/toxins11020112>.
- Taer, A. N., Posesano, G. P. & Masuhay, E. P.** (2020). Potency of phytobiotics in herbal spices as an antimicrobial growth promoter in broiler chicken diets: A Review. *Int. J. Innov. Res. Tech.*, 5 (2), 571–79.
- Verdiansah** (2016). Kidney Function *Check.CDK-237*, 43 (2), 148–54.
- Winarsih, W., Priosoeryanto, B. P., Lay, B. W., Wibawan, I. W. T. & Kompiang, I. P.** (2008). Microscopical lesion of liver in broiler chicken which probiotic adntinistration and subclinical infection of Salmonella. *Jumal Patology Veteriner Indonesia*, 1 (1), 33–40.
- Wiradimadja, R., Widjastuti, T., Rusmana, D. & Abun** (2018). The Performance of Sentul chicken on developer phase offered with different levels of turmeric powder (*Curcuma Domestica*, Val) as feed additives. *Jurnal Ilmu Ternak*, 18 (1), 53–59. <https://doi.org/10.24198/jit.v18i1.18394>.
- Yendy, S. A., Mangisah, I. & Sukamto, B.** (2014). The effect of citric acids addition in diets as acidifier on calcium and phosphor retention of the local male ducks. *Anim. Agric. J.*, 3(1), 70–78. <http://ejournal-s1.undip.ac.id/index.php/aaj>.
- Zainuddin, Masyita D., Sarayulis, S., Jalaluddin, M., Rahmi, E. & Nasution, I.** (2016). Histological feature of intestinal glands of native chicken (*Gallus domesticus*), pigeon (*Columba domesticus*). *J. Med.Vet.*, 10 (1), 9. <https://doi.org/10.21157/j.med.vet.v10i1.4028>.
- Zhang, S. & Chen, D. C.** (2019). Facing a new challenge: The adverse effects of antibiotics on gut microbiota and host immunity. *Chin. Med. J.*, 132 (10), 1135–38. <https://doi.org/10.1097/CM9.0000000000000245>.